




Fakulta rybnářství  
a ochrany vod  
Faculty of Fisheries  
and Protection  
of Waters

Jihočeská univerzita  
v Českých Budějovicích  
University of South Bohemia  
in České Budějovice



Fakulta rybnářství  
a ochrany vod  
Faculty of Fisheries  
and Protection  
of Waters

Jihočeská univerzita  
v Českých Budějovicích  
University of South Bohemia  
in České Budějovice

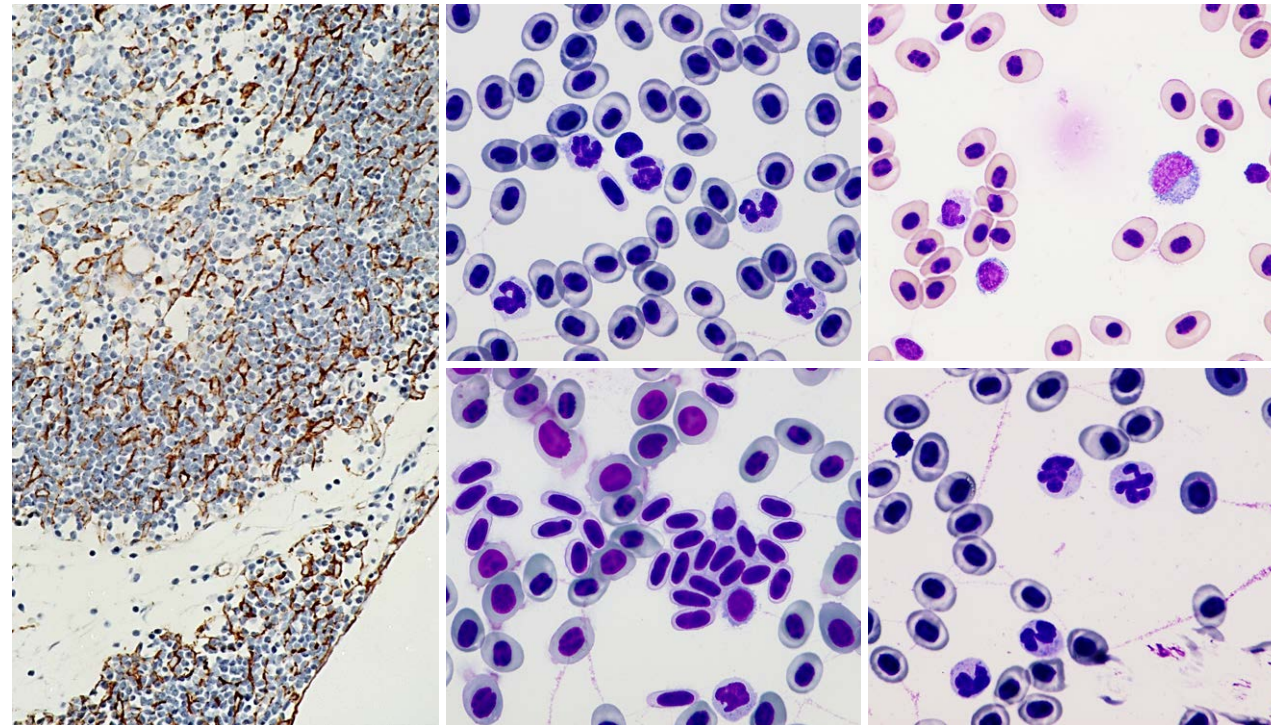
2021



## Methodical approaches to examination of lymphoid tissues in sturgeons

Metodické přístupy k vyšetření lymfoidních  
tkání jeseterů

Methodical approaches to examination of lymphoid tissues in sturgeons



Doctoral thesis by  
Eva Šálková





Fakulta rybnářství  
a ochrany vod  
Faculty of Fisheries  
and Protection  
of Waters

Jihočeská univerzita  
v Českých Budějovicích  
University of South Bohemia  
in České Budějovice

# **Methodical approaches to examination of lymphoid tissues in sturgeons**

**Metodické přístupy k vyšetření lymfoidních tkání jeseterů**

*Doctoral thesis by  
Eva Šálková*

*I, Eva Šálková, thereby declare that I wrote the Ph.D. thesis myself using results of my own work or collaborative work of me and colleagues and with help of other publication resources which are properly cited.*

*I hereby declare that, in accordance with the § 47b Act No. 111/1998 Coll., as amended, I agree with publicizing of my Ph.D. thesis in full version electronically in a publicly accessible part of the STAG database operated by the University of South Bohemia in České Budějovice on its web sites, with keeping my copyright to the submitted text of this Ph.D. thesis. I also agree so that the same electronic way, in accordance with above mentioned provision of the Act No. 111/1998 Coll., was used for publicizing reviews of supervisor and reviewers of the thesis as well as record about the progress and result of the thesis defence. I also agree with comparing the text of my Ph.D. thesis with a database of theses "Theses.cz" operated by National Register of university theses and system for detecting of plagiarisms.*

*In Vodňany 23<sup>rd</sup> April, 2021*

**Supervisor:**

Prof. Martin Flajšhans  
University of South Bohemia in České Budějovice (USB)  
Faculty of Fisheries and Protection of Waters (FFPW)  
Research Institute of Fish Culture and Hydrobiology (RIFCH)  
Zátiší 728/II, 389 25 Vodňany, Czech Republic

**Head of Laboratory of Molecular, Cellular and Quantitative Genetics:**

Prof. Martin Flajšhans

**Dean of Faculty of Fisheries and Protection of Waters:**

Prof. Pavel Kozák

**Board of doctorate study defence with reviewers:**

Prof. Lukáš Kalous – head of the board  
Prof. Petr Ráb – board member  
Prof. Ondřej Slavík – board member  
Assoc. Prof. Jiří Patoka – board member  
Assoc. Prof. Martin Kocour – board member  
Assoc. Prof. Tomáš Polícar – board member  
Assoc. Prof. Zdeněk Adámek – board member

Assoc. Prof. Miroslava Palíková, University of Veterinary Sciences Brno, Czech Republic – thesis reviewer  
Doz. Dr. med. vet. Heike Schmidt-Posthaus, University of Bern, Switzerland – thesis reviewer

**Date, hour and place of Ph.D. defence:**

15<sup>th</sup> September 2021 at 13:00, in USB, FFPW, RIFCH, Vodňany, Czech Republic

**Name:** Eva Šálková

**Title of thesis:**

Methodical approaches to examination of lymphoid tissues in sturgeons  
Metodické přístupy k vyšetření lymfoidních tkání jeseterů

---

*Ph.D. thesis, USB FFPW, RIFCH, Vodňany, 2021, 80 pages, with the summary in English and Czech.*

*Graphic design & technical realisation: JENA Šumperk, [www.jenasumperk.cz](http://www.jenasumperk.cz)*

*ISBN 978-80-7514-132-3*

## CONTENT

### CHAPTER 1

7

General introduction

### CHAPTER 2

31

The first finding of Hassall's corpuscles in the thymi of cultured sturgeons

### CHAPTER 3

37

Immunohistochemical mapping of thymic microenvironment in sterlet  
(*Acipenser ruthenus*)

### CHAPTER 4

47

Examination of white blood cell parameters for three different ploidy level sturgeon species reared in an indoor recirculation aquaculture system for one year

### CHAPTER 5

65

General discussion

67

English summary

74

Czech summary

75

Acknowledgements

77

List of publications

78

Training and supervision plan during study

79

*Curriculum vitae*

80

## **CHAPTER 1**

---

### **GENERAL INTRODUCTION**

---





---

## 1.1. Introduction

---

Sturgeons (Acipenseridae) represent an ancient group of fish which are believed to be 'living fossils'. They also belong to the most endangered fish because of both the commercial overexploitation and poaching as a source of the black caviar, one of the most appreciated delicacies. They firstly appeared already during the Jurassic period (230–200 millions of years ago) (Peng et al., 2007). Their primitive characteristics (large body size, heterocercal tail, cartilaginous skeleton) and their ability to live both in freshwater and marine environment make them interesting for study their histology, physiology, genetics, as well as their broader evolutionary significance. Sturgeons are naturally distributed exclusively in the Northern Hemisphere and reproduce in freshwater. Sturgeons belong to long living fishes, mature very late, do not reproduce annually. Spawning rates are once in 2–11 years for females and 1–6 years for males (Baruš and Oliva, 1995). During their long lives, sturgeons have to face to attacks of many infectious agents (bacteria, viruses, parasites). It is absolutely essential to have a well-developed immune system to be able to survive and live long life. This was one of the reasons why we have focused on the detailed histological examination of lymphoid and haematopoietic tissues and haematological examination of white blood cell parameters.

### Objectives of the thesis:

The current study was devoted to comprehensive approaches in examination of lymphoid tissues in sturgeons. Tested fish were chosen as representatives of particular ploidy level groups: sterlet, *Acipenser ruthenus* represented a functionally diploid group (2n), Russian sturgeon, *Acipenser gueldenstaedtii* was from the functionally tetraploid group (4n) and shortnose sturgeon, *Acipenser brevirostrum* was a functionally hexaploid group (6n) representative. The following objectives were pursued:

1. Histological examination of lymphoid and haematopoietic tissues.
2. Immunohistochemical mapping of the thymus, the main lymphoid organ in sturgeons.
3. Examination of white blood cells parameters for three different ploidy level sturgeon species reared in an indoor recirculation aquaculture system for one year.

---

## 1.2. Fish polyploidy and its impact on their physiology

---

### 1.2.1. General considerations

---

Generally, diploid individuals possess two complete chromosomal sets in somatic cells. Polyploid individuals have the additional chromosome set or sets in somatic cells. The polyploidy is quite common in plants, and so in animals, especially in invertebrates and lower vertebrates up to reptiles. Polyploidy is not commonly seen in birds and mammals. The polyploidy appears to be a significant phenomenon in the evolution of vertebrates and so as well as in fishes.

Naturally occurring polyploids fall into either occasional spontaneous triploid or even tetraploid individuals, or self-sustaining triploid or tetraploid population with atypical modes of reproduction (Benfey, 1999). Such naturally occurring polyploid complex was described e.g. in Eurasian family Cobitidae, in its two genera, *Cobitis* and *Misgurnus*. Polyploid complex consists of diploid, triploid and tetraploid individuals. Mode of reproduction should be should be bisexual, or using alternative reproductive strategies associated with allopolyploidy as exemplified e.g. by Li et al. (2011).

Polyploid fishes can be artificially produced, generally with the aim of producing sterile populations for aquaculture or fisheries management. Triploidy should be achieved using

thermal or hydrostatic pressure shock of eggs shortly after fertilization (Benfey, 1999; Flajshans and Vajcova, 2002; Maxime, 2008; Havelka et al., 2011; Svobodová et al., 2012).

Higher ploidy level means the enlargement both of the cell and the nucleus. Larger cell volume is balanced by reduced cell numbers, reduced cellular and nuclear surface area per unit volume (Benfey, 1999; Palikova et al., 1999; Beyea et al., 2005; Maxime, 2008). The effect of triploidy on cell size is clearly demonstrated for erythrocytes which have larger cell volume when compared to the diploids (Palikova et al., 1999; Wlasow and Fopp-Bayat, 2011). This knowledge is often used to confirm ploidy level in fish. No effect of triploidy on haematocrit was detected. Absolute amount of haemoglobin per cell is slightly higher in triploid comparing diploids (Benfey, 1999). Differences registered in leukocyte count and differential white blood cells count may indicate a ploidy specificity in sturgeons (Palikova et al., 1999; Flajshans and Vajcova, 2002). We list other tissues for which increased nuclear/cellular dimensions and/or decreased nuclear/cellular numbers have been documented in polyploid fishes: brain, retina, epithelium, cartilage, muscle, liver (hepatocytes), kidney (pronephric ducts), ovary and testis (Benfey, 1999).

Common thought is that triploid should grow faster than diploids, but literature about growth rates of triploid fish is inconclusive (Maxime, 2008). Triploids generally have similar morphological and meristic characteristics as diploids (Benfey, 1999; Maxime, 2008). Triploidy is often associated with skeletal and anatomical malformations (e.g. lower jaw deformity, reduction of the number of the vertebrae). Triploid females are frequently observed to have larger fat deposits around the viscera comparing with maturing diploid females (Maxime, 2008). Buchtová et al. (2004) demonstrated significant differences in the distribution of saturated and polyunsaturated fatty acids in muscle lipids. Triploids are thought to have a high potential of tissue regeneration, and a lower tumour incidence. Triploids appeared to have a lower respiratory efficiency than diploids according to reduced gill surface area (Maxime, 2008), and microscopically, structural differences in triploid gill lamellae comparing with diploids were found to support this finding (Flajšhans and Piačková, 2006). According to Benfey (1999), triploid fishes are unable to cope well with chronic stress which results from lower hypoxia tolerance. No difference in haematocrit, plasma cortisol and glucose profile was found after an acute handling stress between triploids and diploids.

Changes in metabolic pathways are more temperature-dependent in triploids than in diploids. Any rise of water temperature lowers oxygen solubility, enhances energy requirements, lessens haemoglobin affinity for oxygen and limits aerobic capacity. Conflicting results given in literature do not enable to conclude a task concerning greater or lower sensitivity of triploids to increase in temperature (Maxime, 2008). According to Benfey (1999), complement and phagocytic activities are similar for diploids and triploids. Triploids may have an increased cellular phagocytic activity, this should be balanced by reduced leukocyte numbers. Triploids are equally as responsive to vaccination as diploids, and no difference in disease susceptibility after exposure to various viral and bacterial pathogens was reported (Benfey, 1999; Maxime, 2008). Triploids appear to have reduced disease resistance, average time to death was shorter in triploids (Benfey, 1999).

In triploid fish, meiosis is seriously affected because three homologous chromosomes cannot correctly pair during the zygotene stage of prophase I. This impairment interferes with gonadal development and gametogenesis (Tiwarý et al., 2004; Piferrer et al., 2009). Ovarian growth is greatly retarded. Triploid females typically do not show any endocrine signs of sexual maturation, do not produce mature oocytes. Ovaries may be hidden in deposits of perivisceral fat in abdominal cavity. Microscopically, ovaries contain only small numbers of oogonia and very few developing primary oocytes. Triploid female rarely produces eggs, but if they do, eggs are undeveloped, infertile.

Although meiosis is also impaired in males, testes grow to near normal size, with a considerable population of fully functional steroidogenic cells (Tiwary et al., 2004; Piferrer et al., 2009). Triploid males exhibit normal pattern of endocrine changes associated with reproduction, and produce viable spermatozoa, but reduced in number, resulting dilute milt. Spermatogenesis in triploids may result in production of aneuploid sperms. Abnormalities in spermatozoan morphology was also reported. When paired with ovulated diploid females in appropriate environment, triploid males show normal spawning behaviour (Benfey, 1999).

### 1.2.2. Polyploidy in sturgeons

---

According to comparative genomic analysis, genome evolution of vertebrates is probably connected with three total genome duplication events. The first duplication event is thought to stand at the background of the evolution of vertebrates itself, the second event is connected with the development of *Gnathostoma*. These two genome duplications are known in literature as 2R ("two rounds") hypothesis. The last third duplication event (and then finally formulated as the 3R hypothesis) led to the development of *Teleostei* and occurred in time when *Teleostei* were separated from sturgeons (Acipenseridae) and paddlefishes (Polyodontidae) (Voff, 2005; Peng et al., 2007). The study of sturgeon genetics can provide valuable data on mechanisms underlying the evolution of vertebrates. Sturgeons have evolved *via* allopolyploidization (Gregory and Witt, 2008; Smith and Gregory, 2009) by several polyploidization and hybridization events. The extant species of the genera *Acipenser*, *Huso*, *Scaphirhynchus* and *Pseudoscaphirhynchus* are separated into different classes according to chromosome numbers: (1) species with 120 chromosomes; (2) species with 250 chromosomes; (3) one species only, *Acipenser brevirostrum* Lesueur, 1818, having 360 chromosomes (Ludwig et al., 2001; Peng et al., 2007; Havelka et al., 2011, 2016). Havelka et al. (2011) stated that two scales of sturgeon ploidy levels are recognized upon their chromosome numbers at present: the evolutionary scale, which presumes tetraploid (4n) – octaploid (8n) – dodecaploid (12n) relationships, referring to ancient ploidy levels, and the functional scale, which presumes diploid (2n) – tetraploid (4n) – hexaploid (6n) relationships arising from significant functional genome re-diploidization in sturgeon evolution.

Sturgeons exhibit large genomes among fishes (Gregory and Witt, 2008; Smith and Gregory, 2009). The increasing number of chromosomes is closely connected with the increase in DNA content in the cell nuclei. Cell and nuclear size correlate in a strongly positive manner with genome size and with each other at each taxonomic level, independently of phylogenetics and of ancient- or neopolyploid status (Hardie and Hebert, 2003). Cytological features such as nuclear volume, cell volume, cell surface area and nuclear surface area also correlate in a positive manner with genome size (Palikova et al., 1999; Hardie and Hebert, 2003; Flajshans et al., 2011).

Over years, the techniques determining ploidy level have been refined. Among direct methods, erythrocyte cellular and nuclear dimensions were applied, following by karyotyping or DNA content quantification. Numerous studies pointed out that erythrocyte cellular and nuclear dimension increased in higher ploidy level groups (Arefjev and Nikolaev, 1991; Benfey, 1999; Hardie and Hebert, 2003; Beyea et al., 2005; Maxime, 2008; Flajshans et al., 2011; Havelka et al., 2011). Increased size is not uniform in all dimensions, a greater proportional increase in cellular and/or nuclear length than in width (Benfey, 1999; Beyea et al., 2005), and thus an alteration in erythrocyte shape should be present. In addition, capillary diameter and heart size remained same in diploids and triploids. A proportionately greater increase in erythrocyte length than in width and high deformability of erythrocytes contribute that blood flow dynamics through capillaries may not be affected in higher ploidy level groups

(Benfey, 1999). Study pointing out cellular and nuclear dimension changes in leukocytes was performed by Palíková et al. (1999) and discussed by Hardie and Hebert (2003).

---

### 1.3. Haematology in sturgeons

---

Haematology concerns the study of solid haematopoietic and lymphoid organs, as well as blood, a liquid tissue with its cellular components. While histology and immunohistochemistry, respectively, are the main investigative tools for solid organs examination, and in that kind, tissue samples are required for assessment, blood as liquid compartment is easily accessible for testing by vessel puncture.

In our studies, we performed histological examination of haematopoietic and lymphoid organs in *Acipenser ruthenus* and *Acipenser brevirostrum*, subsequently completed with immunohistochemical mapping of the thymic microenvironment. The results are summarized in studies by Salkova and Flajshans (2016) (see Chapter 2) and Salkova et al. (2020) (see Chapter 3).

Haematological examination of blood was focused on white blood cell parameters investigation, that reflect physiological status and play an important role in the diagnosis of different pathological conditions. *Acipenser ruthenus*, *Acipenser gueldenstaedtii* and *Acipenser brevirostrum* were encountered in a study running in a period of one year. Fishes were sampled monthly, and total number of leukocytes and differential counts were performed. Results were summarized, evaluated, and prepared for publication, currently reviewed by Veterinary Medicine. Manuscript is attached (see Chapter 4) and describes changes in white blood cell parameters depending on ploidy level, seasonality, and species specificity. Haematological examination of white blood cell parameters thus represents a quite simple, easily accessible, valuable indicator for lymphoid and immune system investigation and testing.

---

#### 1.3.1. Histological examination of haematopoietic and lymphoid organs

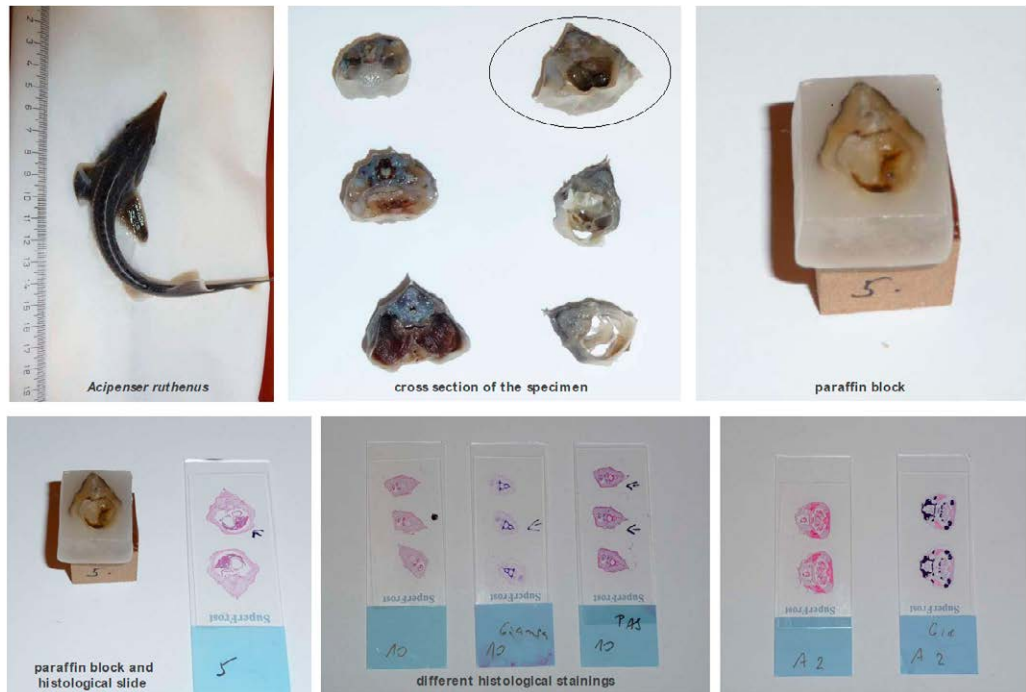
---

Histology, which represents the microscopic evaluation of tissue and organs, has been successfully applied in the veterinary science, including ichthyology. For histological purposes, only fresh tissue samples should be considered. To preserve the morphology of the tissue and to block autolysis, the fixation is necessary. 10% neutral-buffered formalin is the most common fixing agent in the histological laboratory (Roberts and Ellis, 2012). After fixation, the tissue samples are embedded in the paraffin, the tissue blocks are made and the tissue sections with a common thickness of 4 µm are prepared. Obtained slides are stained using haematoxylin and eosin, the basic histological staining. Completed slides are observed under light microscope and the tissue structure is evaluated. If necessary, the advanced histological staining procedure should be applied on the fish tissues (e.g. mucin and azan staining, periodic acid-Schiff (PAS) staining, trichrome, Giemsa and alcian blue staining, Gömöri staining using silver for impregnation of reticular fibres or Perls reaction for iron detection). Such results should contribute to final histological report and tissue assessment.

In our study, the histological examination was performed on juvenile functionally diploid sterlet, *Acipenser ruthenus* and juvenile functionally hexaploid *Acipenser brevirostrum*. The whole specimens were fixed in 10% neutral-buffered formalin. The tissue was conventionally processed, tissue sections were prepared and stained with haematoxylin and eosin (HE). Obtained slides were inspected under Olympus HBS microscope. The description of haematopoietic and lymphoid tissues was performed. Advanced histological staining methods were applied: Giemsa, PAS staining, alcian blue, mucin staining, Perls reaction. Results of

advanced histological staining methods helped to map the nature of haematopoietic cells, and melano-macrophages centres, respectively. Histological procedure is documented in Figure 1.

When performing histological examination of the thymus, Hassall's corpuscles were detected. According to mammalian criteria for morphological assessment (Asghar et al., 2012), juvenile and premature type of Hassall's corpuscles were observed (Salkova and Flajshans, 2016).



**Figure 1.** Histological examination.

The fish specimen is fixed in 10% neutral-buffered formalin, after fixation is cut into small pieces. Tissue is embedded in paraffin and tissue blocks are prepared. The 4  $\mu$ m tissue sections are cut and stained in haematoxylin and eosin. The final tissue slide is inspected under light microscope. Advanced histological staining methods may be performed on demand.

### 1.3.2. Immunohistochemical examination

Immunohistochemistry (IHC) is a laboratory method widely used to characterize tissue and cell origin, both in human and veterinary medicine (Ramos-Vara et al., 2008). In fish, however, little is known about staining characteristics of most tissue types, and especially for less studied chondrosteian fish. In fish, IHC is used in physiological studies that are mapping the antigen distribution and setting on the different cell types and tissues under physiological conditions (Salkova et al., 2020). IHC also is an important and powerful investigative tool in pathology, including infectious diseases (Jorgensen et al., 2009; Dezfuli et al., 2014) or neoplastic lesions (Paquette et al., 2015; Yasumoto et al., 2015; Iaria et al., 2019).

Pre-analytic phase of IHC covers the tissue slide preparation. The fresh tissue is highly recommended and fixation using 10% neutral-buffered formalin is favoured to different fixing agents (e.g. 96% ethanol, Bouin's fluid). It is followed by analytical phase which comprises antigen retrieval procedure, primary antibody application and incubation in a humidity

chamber at 4 °C, usually overnight. The antigen-antibody complex signal is amplified using a detection system. Detection system is represented by a secondary antibody that is carrying the label (enzyme, labelled polymer), and is applied to bind with the primary antibody. The antigen-antibody complex is finally visualized using 3–3' diaminobenzidine tetrahydrochloride (DAB) as a chromogen, that produced a brown end product. Harris's haematoxylin is used to perform nuclear counterstaining and tissue overview.

Both monoclonal and polyclonal antibodies are used in IHC (Ramos-Vara, 2005; Ruiz et al., 2005; Ramos-Vara et al., 2008; Jorgensen et al., 2009). Most antibodies are of mammalian origin (i.e. mouse, rabbit, or goat). Monoclonal antibodies bind to a single epitope of an antigen and thus provide high specificity. Polyclonal antibodies contain antibodies against a wide range of epitopes (Ramos-Vara, 2005; Ramos-Vara and Miller, 2014). Their specificity may therefore be lower, and sensitivity higher compared to monoclonal antibodies. Greater non-specific background staining may be present when using polyclonal antibodies, and cross-reactivity may be found in cases when target tissue antigen epitopes are shared with other proteins. Knowledge of the proper antigen setting, including location of the positive reaction patterns, is therefore important when interpreting the results obtained (Ramos-Vara, 2005).

In our study, we performed the immunohistochemical examination of the sterlet's thymus. Investigated markers were chosen as representatives of epithelial (cytokeratin AE1/AE3), mesenchymal (vimentin), neuroectodermal (S-100 protein), lymphoid (CD3 and LCA, leukocyte common antigen) structures of the thymic microenvironment. More detailed information concerning antibody type application, antigen description and discussion about human antibody application in the ichthyology is mentioned in our study (Salkova et al., 2020). Recommendation regarding fish species antibody development is also stated *ibidem*.

### 1.3.3. Haematological examination

Haematological examination of fishes is a useful and important diagnostic tool for evaluation the physiological status and plays an important role in the diagnosis of different pathological conditions (e.g. inflammatory and non-inflammatory diseases, water pollution, stress). Comparing histological examination (tissue demand, laboratory equipment, time demands), haematological evaluation seems to be minimally invasive (blood is easily accessible by vessel puncture), should be performed repeatedly and blood puncture is completed in one minute. There are also some pitfalls accompanying the haematological examination – to avoid rapid blood clotting, the blood samples are taken to heparin-coated syringe. The blood smear is recommended to be performed immediately after the sampling, dried at room temperature, fixed with methanol and stained using e.g. Hemacolor® Rapid staining set (Merck KGaG, Darmstadt, Germany).

Basic haematological parameters are represented by red blood cell indices (red blood cell counts, haematocrit, haemoglobin concentration, mean corpuscular volume, mean corpuscular haemoglobin and mean corpuscular haemoglobin concentration), white blood cell indices (white blood cell count and differential white blood cell count), and platelets count (Knowles et al., 2006; Zexia et al., 2007; Docan et al., 2012; Svobodova et al., 2012). Physiologically, all developmental stages of erythrocytes and leukocytes are present in the peripheral blood (Svobodova et al., 2012). When performing differential leukocyte count, only mature cells are involved, while blasts and vanishing cells are excluded. The presence of all developmental stages in the peripheral blood represents one of the reasons why light microscopical assessment is favoured compared to computed processing. When evaluating white blood cell parameters, internal (e.g. ploidy level, age, sex and spawning activity, diet) and external conditions (e.g. water chemistry, indoor or outdoor breeding, temperature, light) should be taken in account.

In our study, the tested fishes were chosen as representatives of particular ploidy level groups. According to Havelka et al. (2011), *Acipenser ruthenus* represented functionally diploid group (2n), *Acipenser gueldenstaedtii* was from the tetraploid group (4n) and *Acipenser brevirostrum* was the functionally hexaploid (6n) representative. All fishes originated from the Genetic Fisheries Centre of the Faculty of Fisheries and Protection of Waters, University of South Bohemia in Ceske Budejovice, Czech Republic. The study was carried out in accordance with the Czech Law No. 246/1992 'Animal welfare'. Protocols were supervised by the Institutional Animal Care and Use Committee (IACUC) of the University of South Bohemia (USB), Faculty of Fisheries and Protection of Waters (FFPW) in Vodňany. The USB FFPW has the approval of the Ministry of Agriculture of the Czech Republic for handling and usage of experimental animals (ref. no. 16OZ15759/2013-17214).

#### 1.3.3.1. Total number of leukocytes

---

Total number of leukocytes is recorded in  $10^9/L$ , represents the basic parameter reflecting fish physiological or immunological status, respectively. Increased or decreased total number of leukocytes reflects the pathological conditions including inflammatory and non-inflammatory diseases, mechanical injury, water pollution or stress condition.

In our study, blood samples for total number of leukocyte determination were stored in heparinized tubes and placed on ice until further analysis, but no longer than one hour. Heparinized blood was diluted 200 times with solution containing NaCl,  $Na_2SO_4$ ,  $Na_2HPO_4 \cdot 12H_2O$ ,  $KH_2PO_4$ , formaldehyd and 1% cresyl violet diluted in distilled water (Svobodova et al., 2012). Total number of leukocytes was performed by counting white blood cells in a Bürker chamber and was recorded in  $10^9/L$  (Knowles et al., 2006; Svobodova et al., 2012). Thrombocytes and thrombocyte-like cells were not included in white blood cells parameters, since they represent distinct blood cell component (Khandekar et al., 2012).

#### 1.3.3.2. Differential white blood cell count

---

Differential white blood cell count shows a percentage of particular cell type and is recorded in % (Knowles et al., 2006; Svobodova et al., 2012). Blood smear is prepared immediately after blood sampling and two hundred leukocytes are determined and counted for each specimen. Cellular size, nuclear morphology, cytoplasmic staining patterns are the criteria for cells identification and determination (Ellis, 1977; Ainsworth, 1992; Knowles et al., 2006; Zexia et al., 2007; Svobodova et al., 2012). Changes in differential counts should point at particular fish pathology (e.g. bacterial, viral, mycotic infections, haematopoietic disorders, poisoning, stress, nutrition disorders).

In our study, differentia count was performed for representative of diploid, tetraploid and hexaploid sturgeons. The blood smears were inspected under an Olympus BHS microscope using x1,000 magnification. Lymphocytes, granulocytes, monocytes were determined. Granulocytes were further classified as neutrophils and eosinophils, and in each subgroup the bands and segments were counted. The number of nuclear segments in neutrophils and eosinophils was also established for each ploidy level group.

Data concerning seasonal and annual variation are still under review in Veterinary Medicine.

---

## 1.4. Haematopoiesis in lower vertebrates

---

In phylogenetically less advanced species including fish, haematopoiesis is taking place in diverse organs such as kidney, spleen, intestine, liver as well as in circulatory space (Fänge, 1986; Tavassoli, 1986). None of these organs possess the organization of marrow known from higher vertebrates. Haematopoietic tissue is thus accessory and supplementary component of above-mentioned organs, located often interstitially, rather than a separate organ. Phylogenetically, the bone marrow first appears in Anuran amphibian (Tavassoli, 1986). On the other hand, lymphopoiesis takes place in the thymus, which represents the main lymphoid organ already documented in elasmobranchs and cartilaginous fish (Fänge, 1986; Petrie-Hanson and Petermann, 2005).

It is remarkable to mention some distinct structures and tissues encountered in haematopoiesis in phylogenetically less advanced species. In *Chondrichthyes*, Leydig organ, epigonal organ and spleen constitute lymphomyeloid tissues. Leydig organ is bone marrow-like tissue situated between the muscularis and the mucosa of the esophagus. Leydig organ produces granulocytes and lymphocytes and represents a part of the immune system (Mattisson and Fänge, 1982; Honma et al., 1984). Epigonal organ is the largest lymphomyeloid organ, which envelops the gonads, also posterior region of intestine and reaches up the rectal gland (Fänge and Mattisson, 1981; Honma et al., 1984; Manca et al., 2019).

In *Chondrostei*, meningeal myeloid tissue, cardiac/pericardial myeloid are observed (Scharrer, 1944; Catton, 1951; Fänge, 1986; Tavassoli, 1986; Gradil et al., 2014). Histological description and function is mentioned further ahead.

---

### 1.4.1. Lymphoid organs and tissues in sturgeons

---

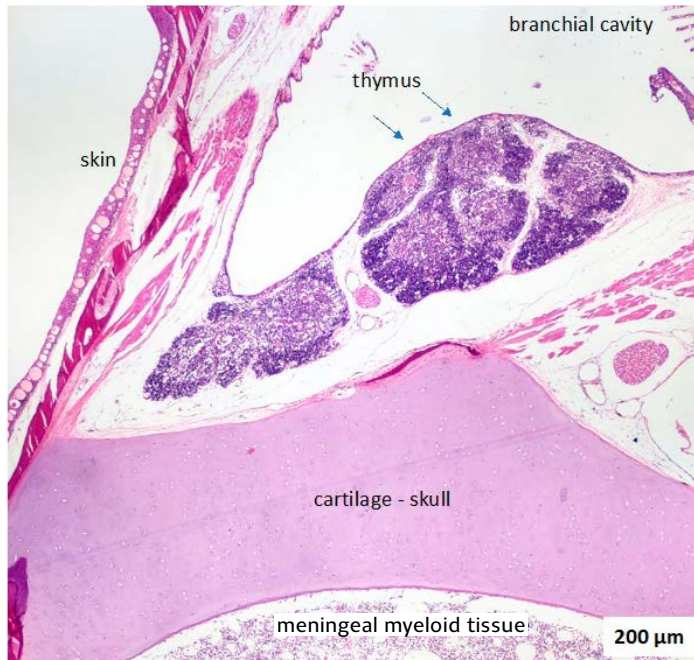
#### 1.4.1.1. Thymus

---

The thymus represents the main lymphoid organ in sturgeons (Fänge, 1986), it is a site of lymphocyte development. The thymus in fish is a pair lymphoepithelial organ lying on the upper inside edge of the operculum, just beneath the cuboidal or flat epithelium covering the branchial cavity (Roberts and Ellis, 2012; Salkova and Flajshans, 2016). Embryologically, the thymus is derived from the third pharyngeal pouch. Thymi in sturgeons persist until the fish reach the sexual maturity. Later these undergo the process of age-related atrophy (Fänge, 1986; Bowden et al., 2005). Histologically, a thin fibrous capsule covers the thymic surface. The thymus is lobulated and organized in outer cortex enclosing the central medulla (Petrie-Hanson and Petermann, 2005; Salkova and Flajshans, 2016). A diversity of different cell types is found within the thymus. The cortex is predominantly composed of closely packed lymphocytes. The medulla is composed of sparsely organized lymphocytes, macrophages, reticular cells, tinny vascular channels and Hassall's corpuscles that have a dispersed distribution (Fänge, 1986; Petrie-Hanson and Petermann, 2005; Petermann and Petrie-Hanson, 2006; Salkova and Flajshans, 2016).

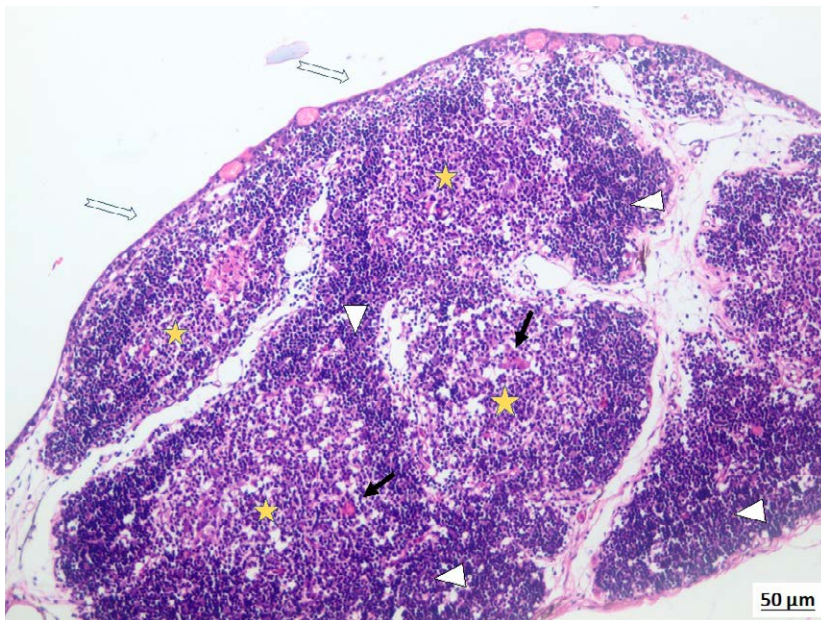
Hassall's corpuscles are components of non-lymphocytic microenvironment of the thymic medulla. Histologically, the corpuscles are rounded or spherical epithelial structures varying in diameter. They are composed of eosinophilic reticulo-epithelial cells, often concentrically arranged (Salkova and Flajshans, 2016). The central part of the corpuscle may undergo the process of degeneration. Regressive changes including hyalinization, calcification and cyst formation should also be found. The number of Hassall's corpuscles may vary according to the age, the course of disease or the presence of stress (Furukawa, 2012). The thymic topography is illustrated in Figure 2. The thymic structure is demonstrated in Figure 3.





**Figure 2.** Thymic topography, haematoxylin and eosin (HE), magnification x40.

The thymus is lying in a close proximity to the branchial cavity, in the upper inside edge of the operculum. The cartilaginous skull represents the boundary between the cranial cavity and adjacent soft tissues.

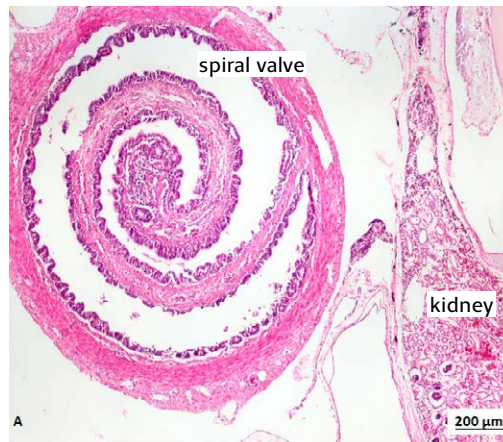


**Figure 3.** The thymic structure, haematoxylin and eosin, magnification x200.

Fine fibrous capsule is situated in the thymic surface. Plain arrows point at the flat or cuboidal epithelium covering the branchial cavity. The thymus is lobulated and consists of outer cortex (illustrated by white arrowheads) and inner medulla (stars). There are juvenile Hassall's corpuscles indicated by black arrows.

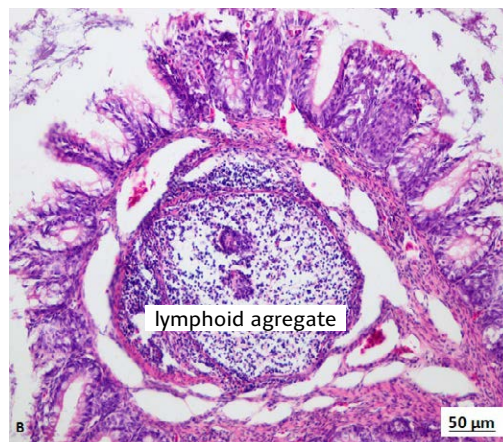
## 1.4.1.2. Intestine

Lymphoid tissue in digestive system constitutes the important barrier function against microbial attacks. In younger individuals, clusters of closely packed lymphocytes, granulocytes and macrophages are situated in *lamina propria mucosae*. In older individuals, follicle-like structure, resembling Peyer's patches in higher vertebrates, should be recognised *ibidem*. Intestinal lymphoid tissue is predominantly found and located in spiral valves (Fänge, 1986; Petermann and Petrie-Hanson, 2006). Topography and structure of spiral valve is illustrated in Figure 4.



**Figure 4A.** Spiral valve, topography, haematoxylin-eosin, magnification x40.

Spiral valve is situated in the distal portion of the intestine, and enlarges the absorption surface. It is worth noted the proximity to the kidney, which is situated dorsally to the intestine. In the distal portion of the renal tissue, glomeruli and excretory tubules dominate, while interstitial haematopoietic tissue is presented only marginally.



**Figure 4B.** Spiral valve, haematoxylin-eosin, magnification x200.

Aggregates of small lymphocytes are situated in *lamina propria mucosae* in the spiral valve. Lymphoid aggregates or clusters, respectively, represent an important barrier function against microbial attacks.

### 1.4.1.3. Other lymphoid tissues

---

Clusters of closely packed lymphocytes or only dispersedly distributed lymphocytes are often present in the skin, in the oral or branchial cavity. Their function is similar to that in digestive system, i.e. barrier function against microbial attacks. These lymphoid clusters do not constitute a true organ or tissue, but play an important role in immune system.

### 1.4.2. Haematopoietic organs in sturgeons

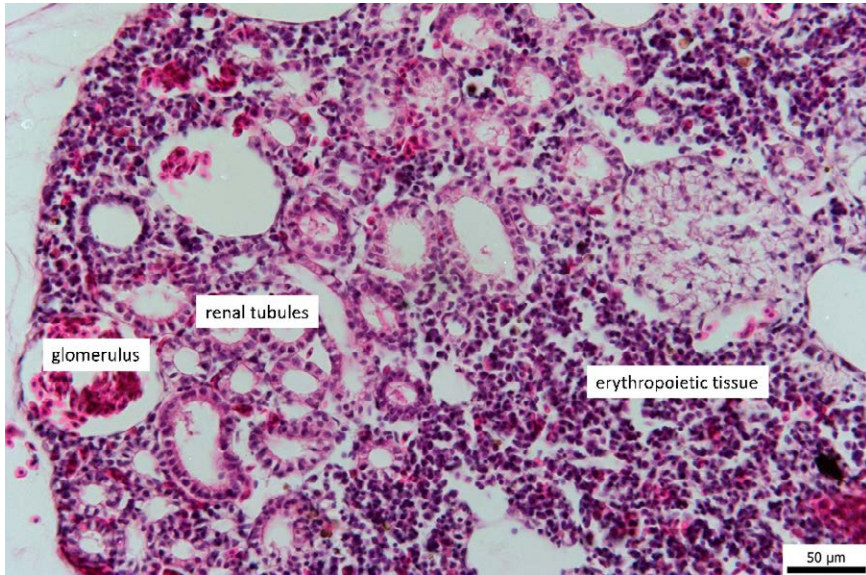
---

#### 1.4.2.1. Kidney

---

In sturgeons, the kidney, especially the anterior portion, is regarded to be the main haematopoietic organ (Fänge, 1986). The kidney consists of excretory (glomeruli and renal tubules) and haematopoietic tissue (Figure 5). Interstitial kidney tissue is reported to be the source of haematopoietic stem cells (for erythropoiesis, granulopoiesis and lymphopoiesis). Haematopoietic capacity is greatest anteriorly and decreases descendantly. Predominantly, erythropoiesis takes place in the head of kidney. With less frequency, granulopoiesis and lymphopoiesis are located there, too. In addition, excretory renal tubules predominate in dorsal portion of the kidney (Fänge, 1986; Charmi, 2010).

Microscopically, blast and immature cells are situated within the renal interstitium, which is composed of reticuloendothelial cells and numerous sinuses (Roberts and Ellis, 2012). Blood flow allows filtration of effete cells and addition of new ones (Roberts and Ellis, 2012). Another cellular structure, often found interstitially in kidney and other haematopoietic organs, is the melano-macrophage centres (MMC) (Agius and Roberts, 2003; Roberts and Ellis, 2012). MMC are aggregates of dark pigmented cells distributed throughout the haematopoietic tissues, especially in older individuals. The pigment is dark brown or black. The nature of pigment is thought to be melanin, lipofuscin, hemosiderin, or ceroid. In healthy fish, the amount of dark pigment in MMC is small. Number of MMC is rising in case of chronic stress, chronic inflammatory conditions, starvation, haemolysis, and, of course, with aging. One explanation should consider their role as a scavenger system (Agius and Roberts, 2003). Morphologically, MMC are usually nodular, composed of pigmented macrophages, may have a rim of lymphocytes.



**Figure 5.** Kidney, haematoxylin and eosin, magnification x400.

Anterior portion of the kidney (head of the kidney) is the main haemopoietic organ in sturgeons, and especially erythropoiesis takes place here. Interstitial tissue, which is composed of reticuloendothelial cells and vascular sinuses, is the site of haematopoietic stem cells. Clusters of developing erythrocytes are presented.

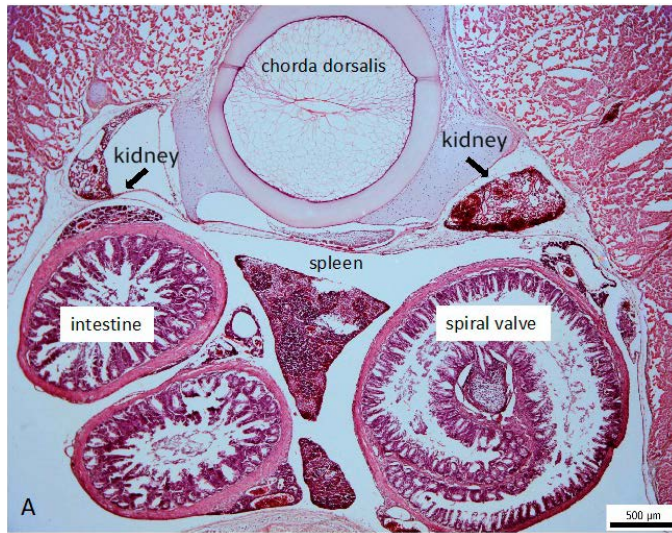
#### 1.4.2.2. Spleen and liver

The spleen is dark red in colour (Fänge, 1986). Microscopically, the fibrous capsule covers the surface, and the parenchyma is composed of red and white pulp. The splenic red pulp consists of sinusoidal phagocytic tissue in which large numbers of erythrocytes may be held, and foci of erythropoietic tissue, which is supported by fibres. White pulp is recognized as follicle-like structure periarterially, and contains lymphocytes, granulocytes, and scattered macrophages. The peripheral rim is constituted by numerous eosinophils and their precursors (Fänge, 1986). Melano-macrophage centres should occur in the spleen (Agius and Roberts, 2003).

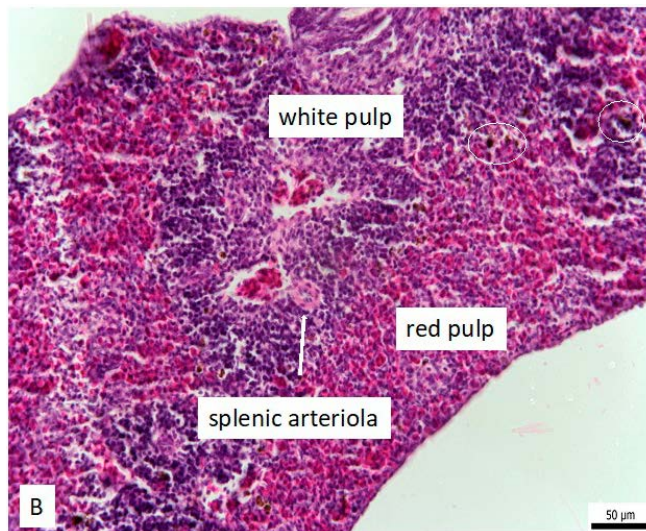
It is obvious, that cranial kidney represents the main haematopoietic, and of course erythropoietic organ in sturgeons, respectively. The spleen is regarded a secondary lymphoid organ. Thus, it is responsible for different functions: immune defence, scavenger system, blood reservoir. Immune defence and scavenger function are the main splenic functions indeed.

Erythropoiesis represents one of the splenic functions, however, in comparison with a cranial kidney which is a main erythropoietic tissue, it acts as a supplementary source of maturing erythrocytes. Erythropoiesis is constituted by dispersedly distributed small foci of maturing erythrocytes, especially in the red splenic pulp (Fänge, 1986). Spleen as a blood reservoir enables blood cells trapping (both white and red blood cells and thrombocytes) and their release into the blood stream (vessels) on demand (Figure 6).

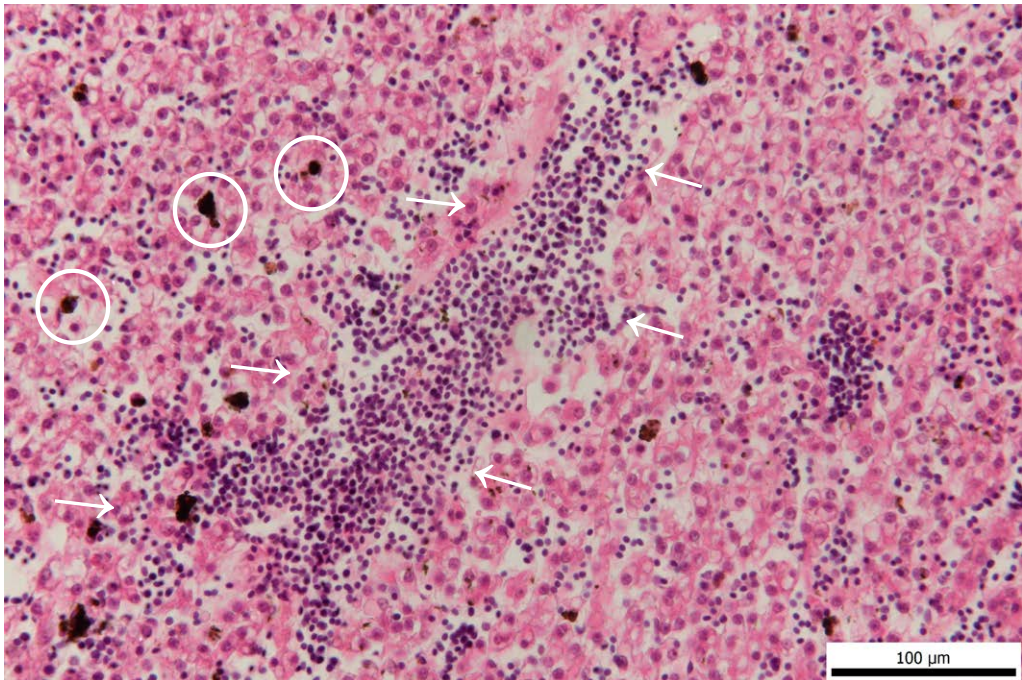
The liver should also be included to haematopoietic organs. Dispersedly distributed islets of mainly erythropoietic tissue are located within the parenchyma, predominantly in periportal areas (Figure 7).



**Figure 6A.** Topography of the spleen, haematoxylin and eosin, magnification x40. The spleen is situated in the abdominal cavity and in close proximity to the intestine anteriorly, to the kidneys dorsally.



**Figure 6B.** Spleen in detail, haematoxylin and eosin, magnification x400. The spleen consists of red and white pulp. Red pulp is constituted with phagocytic sinusoidal tissue admixed with foci of erythropoietic cells. White pulp is located periarterially and is composed of small lymphocytes, scattered macrophages, granulocytes and eosinophils. White circles point at melanomacrophages located at the periphery of white pulp.

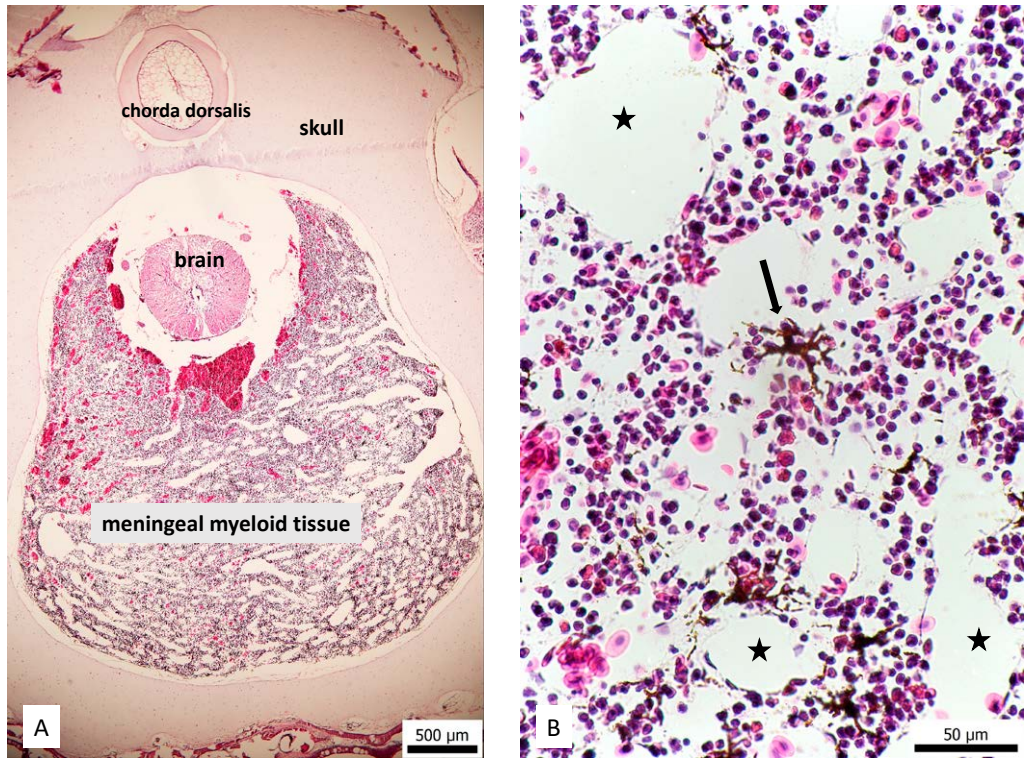


**Figure 7.** Liver, haematoxylin and eosin, magnification x400.

Dispersedly distributed islets of erythropoietic tissue are located within the liver parenchyma (indicated by arrows). White circles point at melano-macrophages centres.

#### 1.4.2.3. Meningeal myeloid tissue

Meningeal myeloid tissue (MMT) is believed to be the site of granulopoiesis in sturgeons, it is located in the cranial cavity above the hind part of the brain, and anterior to notochord (Scharrer, 1944; Fänge, 1986; Gradil et al., 2014; Icardo, 2002; Petermann and Petrie-Hanson, 2006). MMT extends ventrolaterally along central nervous system until the level of the anterior portion of kidney. Microscopically, loosely packed free cells are interspersed within connective tissue, around small arteries, and nerve bundles. The free cells include lymphocytes, granulocytes, and erythrocytes in various stages of development. The release of mature red cells into the circulation is enabled through openings in the walls of the sinusoids (Figure 8).



**Figure 8A.** Topography of meningeal myeloid tissue, magnification x40.

Meningeal myeloid tissue (MMT) is located in the cranial cavity, forms a large mass of tissue around and above the hind part of the brain, and anterior to notochord (chorda dorsalis).

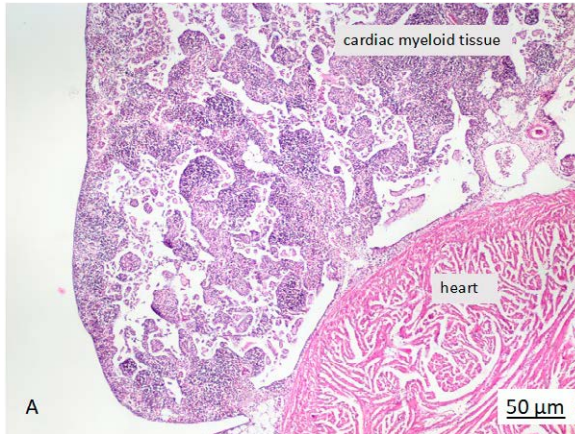
**Figure 8B.** Meningeal myeloid tissue, magnification x600.

Loosely packed clusters or free haematopoietic cells are dispersedly distributed within the fine connective tissue, sinusoids and vascular spaces (sinusoids and vascular spaces are indicated by black stars). Developing granulocytes, erythrocytes, thrombocytes and small lymphocytes are present in small clusters in MMT. Mature cells traverse the sinusoidal wall and enter the circulation. Black arrow points at melano-macrophage centre (note the thin cytoplasmic protrusions resulting in star shape of melano-macrophage centre).

#### 1.4.2.4. Cardiac myeloid tissue

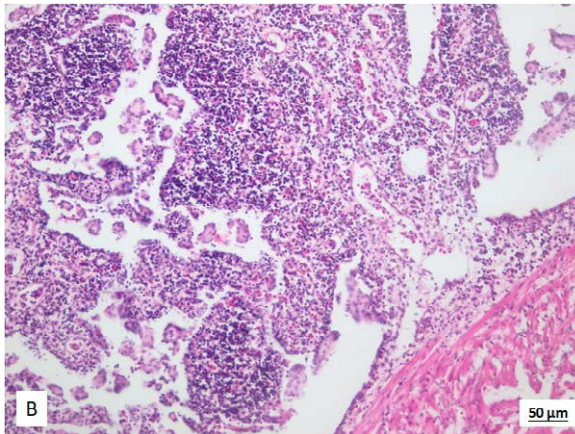
Macroscopically, cardiac myeloid tissue (CMT) covers the epicardium, is greyish or pink in colour, and nodular in arrangement. Microscopically, closely packed cells (predominantly granulocytes, macrophages and lymphocytes as well as a small number of admixed erythrocytes) are separated by venous or lymphatic sinuses. Thus, CMT is a complex lymphohaemopoietic organ (Fänge, 1986; Icardo et al., 2002; Gradil et al., 2014) (Figure 9). CMT plays an important role in establishment and maintenance of the immune responses. Some studies proved the presence of plasma cells in CMT especially after immunization (Petermann and Petrie-Hanson, 2006). In some aspects, the structure of CMT is similar to the thymus, one theory suggests CMT to be a modified thymus with extra erythropoietic capability, without the presence of Hassall's bodies in structure resembling medulla (Icardo et al., 2002). CMT

similarly to the thymus undergoes the atrophy by the time sturgeons reach sexual maturity. In adults, CMT microscopically resembles avian lymph-node-like structure (Fänge, 1986).



**Figure 9A.** Cardiac myeloid tissue, haematoxylin-eosin, magnification x200.

Cardiac myeloid tissue covers the epicardium, and is lobular and nodular in an arrangement. It is composed of closely packed cells including granulocytes, macrophages, small lymphocytes and a small number of admixed erythrocytes. Cellular component is separated by venous or lymphatic sinuses and bands of fibrous tissue. The presence of fibrous bands increase with time and is connected with age related cardiac myeloid tissue atrophy.



**Figure 9B.** Cardiac myeloid tissue, haematoxylin-eosin, magnification x400.

Closely packed granulocytes, macrophages, small lymphocytes constitute aggregates which are separated by thin vascular and lymphoid sinuses.



---

## 1.5. Blood cells

---

### 1.5.1 Erythrocytes

---

The fish erythrocytes are similar in size and tinctorial properties to that of the higher vertebrates. Erythrocytes represent the dominant blood cells component in sturgeons ( $1.23 \times 10^{12}/l$ ). Erythrocytes are nucleated cells with centrally located nuclei. All developmental stages of erythrocytes, including blasts, may be seen in the peripheral blood, such finding is concerned to be physiological (Roberts and Ellis, 2012; Svobodova et al., 2012). It should be noted, that in the peripheral blood, under physiological condition, the number of blasts is low, and usually not exceeding 1–2% from all erythrocytes (Svobodova et al., 2012). By contrast, increasing number of immature erythrocytes should point out the pathological condition, such as hypoxia, poisoning, diseases (Svobodova et al., 2012).

### 1.5.2. Leukocytes

---

Leukocytes are nucleated cells and total number of leukocytes vary in wide physiological ranges ( $14\text{--}40 \times 10^9/L$ ) depending on external conditions (e.g. water chemistry, temperature, feeding, light regimen) and internal conditions (e.g. ploidy level, age, sex, hormonal status, general health condition).

While performing differential white blood cell count, lymphocytes, monocytes and granulocytes are recognized. Lymphocytes dominate in differential count (make up 70–86%), are responsible for the immune response, and are divided into small and large ones, using the criteria of cell size (Ellis, 1977; Zexia et al., 2007; Knowles et al., 2006; Svobodova et al., 2012). Lymphocytes are round or spherical. The nucleus occupies almost the whole cell, only a narrow rim of basophilic cytoplasm remains around the nucleus. Majority of circulating small lymphocytes appears as inactive cells. Lymphocytes are stimulated to action by specific antigens. Thus, large lymphocytes represent different functional state, and plasma cells are believed to be matured lymphocytes (Knowles et al., 2006; Roberts and Ellis, 2012).

Monocytes are large cells with prominent eccentrically located horseshoe-shaped nucleus, slightly basophilic and vacuolated cytoplasm (Palikova et al., 1999; Knowles et al., 2006; Svobodova et al., 2012). Counting from all leukocytes, monocytes constitute 1–2%.

Granulocytes are classified as neutrophils, eosinophils and basophils according to their ultrastructural and histochemical grounds (Ellis, 1977; Ainsworth, 1992; Petrie-Hanson and Peterman, 2005). Generally, in fish under physiological conditions, basophils seem to be rare cell subpopulation (Palikova et al., 1999; Zexia et al., 2007; Svobodova et al., 2012). Basophils constitute less than 1% of all leukocytes, basophilic granules should be detected in the cytoplasm (Roberts and Ellis, 2012). Contrary to the basophils, neutrophils dominate in differential counts, make up 10–20% of all leukocytes, or up to 75–80% from granulocytes, respectively. Neutrophils vary in shapes, the nucleus is slightly basophilic, may occur as band or may be two- or several-segmented. Their cytoplasm is amphiphilic in basic cytological staining procedures, e.g. when using Hemacolor® Rapid staining set. Neutrophils are phagocytic, chemotactic and bactericidal (Roberts and Ellis, 2012).

Eosinophils are commonly found in blood smears of sturgeons. Counting from all leukocytes, eosinophils represent 5–6%, or 15–20% from granulocytes, respectively. Their cytoplasm contains easily recognizable eosinophilic granules. The nuclei are basophilic, may occur as bands or may be two- or several-segmented (Ainsworth, 1992; Svobodova et al., 2012). The number of eosinophils increase in parasitic diseases (Roberts and Ellis, 2012).

### 1.5.3. Thrombocytes

Currently, thrombocytes represent a separate and an independent group of blood cells based on the different origin and different functions comparing the leukocytes. Thus, the thrombocytes should not be encountered into leukocyte counts as was performed by some scientists (e.g. Knowles et al., 2006; Zexia et al., 2007). Thrombocytes are nucleated cells, occur as single cells or form clusters or small groups. Different shapes are recognized – round, oval, fusiform, spindle shape, depending on the amount of the cytoplasm (Svobodova et al., 1986; Palikova et al., 1999; Piackova et al., 2014). Thrombocytes are responsible for blood clotting and play an important role in preventing the loss of tissue fluids from injuries. Their number is similar to the number of leukocytes.

#### References

- Agius, C., Roberts, R.J., 2003. Melano-macrophage centers and their role in fish pathology. *Journal of Fish Diseases*. 26, 499–509.
- Ainsworth, A.J., 1992. Fish granulocytes: morphology, distribution and function. *Annual. Rev. of Fish Diseases* 2, 123–148.
- Arefjev, V.A., Nikolaev, A.I., 1991. Cytological analysis of the reciprocal hybrids between low- and high-chromosome *Acipenserids*, the great sturgeon, *Huso huso* (L.), and the Russian sturgeon, *Acipenser gueldenstaedtii* Brandt. *Cytologia* 56, 495–502.
- Asghar, A., Yunus, M.S., Faruqi, A.N., 2012. Polymorphism of Hassall's corpuscles in thymus of human fetuses. *International Journal of Applied and Basic Medical Research* 2, 7–10.
- Baruš, V., Oliva, O., 1995. Fauna ČR a SR. Mihulovci a ryby I. díl. Academia Praha, 623 pp. (in Czech)
- Benfey, T.J., 1999. The physiology and behaviour of triploid fishes. *Rev. Fish. Sci.* 7, 36–67.
- Beyea, M.M., Benfey, T.J., Kieffer, J.D., 2005. Hematology and stress physiology of juvenile diploid and triploid shortnose sturgeon (*Acipenser brevirostrum*). *Fish Physiol. Biochem.* 31, 303–313.
- Bowden, T.J., Cook, P., Rambout, J.H.W.M., 2005. Development and function of the thymus in teleosts. *Fish Shellfish Immunol.* 19, 413–427.
- Buchtová, H., Smutná, M., Vorlová, L., Svobodová, Z., Flajšhans, M., 2004. Fatty acid composition of diploid and triploid population of tench (*Tinca tinca* L.). *Acta Vet. BRNO* 73, 235–245.
- Catton, W.T., 1951. Blood cell formation in certain teleost fishes. *Blood*. 6, 39–60.
- Charmi, A., Parto, P., Bahmani, M., Kazemi, R., 2010. Morphological and histological study of kidney in juvenile great sturgeon (*Huso huso*) and Persian sturgeon (*Acipenser persicus*). *American-Eurasian Journal of Agriculture and Environmental Sciences* 7, 505–511.
- Dezfuli, B.S., Giari, L., Lorenzoni, M., Manera, M., Noga, E.J., 2014. Perch liver reaction to *Triaenophorus nodulosus* plerocercoids with an emphasis on piscidins 3, 4 and proliferative cell nuclear antigen (PCNA) expression. *Vet. Parasitol.* 200, 104–110.
- Docan, A., Dediú, L., Cristea, V., 2012. Effect of feeding with different dietary protein level on leukocytes population in juvenile Siberian sturgeon, *Acipenser baerii* Brandt. *Archiva Zootechnica* 15, 59–67.
- Ellis, A.E., 1977. A leukocyte of fish: A review. 1977. doi.org/10.1111/j.1095-8649.1977.tb04140.x

- Fänge, R., 1986. Lymphoid organs in sturgeons (Acipenseridae). *Vet. Immunol. Immunopathol.* 12, 153–161.
- Fänge, R., Mattisson, A., 1981. The lymphomyeloid (haemopoietic) system of the Atlantic nurse shark, *Ginglymostoma cirratum*. *The Biological Bulletin.* 160, 240–249.
- Flajshans, M., Vajcova, V., 2000. Odd ploidy levels in sturgeon suggest a backcross of interspecific hybrids to evolutionary tetraploid and/or octaploid parental species. *Folia Zool.* 49, 133–138.
- Flajshans, M., Vajcova, V., 2002. Differences in haematological indices of sturgeons with different ploidy levels. *Biodiverzita Ichtyofauny ČR IV*, pp. 59–64.
- Flajšhans, M., Piačková, V., 2006. Difference in blood and water diffusion distance in gill lamellae of diploid and triploid tench (*Tinca tinca* L.). *J. Fish Biol.* 69, 1870–1873.
- Flajshans, M., Psenicka, M., Rodina, M., Tesitel, J., 2011. Image cytometric measurements of diploid, triploid and tetraploid fish erythrocytes in blood smears reflect the true dimensions of live cells. *Cell Biol. Int.* 35, 67–71.
- Furukawa, S., Wingenfeld, L., Morita, S., Takay, A., Nakagawa, T., Sakaguchi, I., Matsuda, W., Nishi, K., 2012. Histochemical and morphological characteristics of the Hassall's corpuscles. The stress affects involution of the ectopic intra-thyroidal and the normal position thymus and morphological changes of the Hassall's corpuscles. *Journal of Forensic Research* 3–9.
- Gradil, A.M., Wright, G.M., Wadowska, D.W., Fast, M.D., 2014. Ontogeny of the immune system in Acipenserid juvenils. *Dev. Comp. Immunol.* 44, 303–314.
- Gregory, T.R., Witt, J.D.S., 2008. Population size and genome size in fishes: a closer look. *Genome.* 51, 309–313.
- Hardie, D.C., Hebert, P.D.N., 2003. The nucleotypic effects of cellular DNA content in cartilaginous and ray-finned fishes. *Genome* 46, 683–706.
- Havelka, M., Kaspar, V., Hulak, M., Flajshans, M., 2011. Sturgeon genetics and cytogenetics: a review related to ploidy levels and interspecific hybridization. *Folia Zool.* 60, 93–103.
- Havelka, M., Bytyutskyy, D., Symonova, R., Rab, P., Flajshans, M., 2016. The second highest chromosome count among vertebrates is observed in cultured sturgeon and is associated with genome plasticity. *Genet Sel Evol.* 48, 1–9.
- Honma, Y., Okabe, K., Chiba, A., 1984. Comparative histology of Leydig and epigonal organs in some Elasmobranchs. *Jpn. J. Ichthyol.* 31, 47–54.
- Iaria, C., Ieni, A., Corti, I., Puleio, R., Brachelente, C., Mazzullo, G., Lanteri, G., 2019. Immunohistochemical study of four fish tumors. *J. Aquat. Anim. Health* 31, 97–106.
- Icardo, J.M., Colvee, E., Cerra, M.C., Tota, B., 2002. The structure of the conus arteriosus of the sturgeon (*Acipenser naccarii*) heart: II., The myocardium, the subepicardium, and the conus-aorta transition. *The Anatomical Record* 268, 388–398.
- Jorgensen, T.R., Raida, M.K., Kania, P.W., Buchmann, K., 2009. Response of rainbow trout (*Oncorhynchus mykiss*) in skin and fin tissue during infection with a variant of *Gyrodactylus salaris* (Monogenea: Gyrodactylidae). *Folia Parasitica* 56, 251–258.
- Khandekar, G., Kim, S., Jagadeeswaran, P., 2012. Zebrafish thrombocytes: Functions and Origins. *Adv. Hematol.* 2012. doi: 10.1155/2012/857058.
- Knowles, S., Hrubec, T.C., Smith, S.A., Bakal, R.S., 2006. Hematology and plasma chemistry reference intervals for cultured shortnose sturgeon (*Acipenser brevirostrum*). *Vet. Clin. Pathol.* 35, 434–440.

- Li, Y.-J., Yu, Z., Zhang, M.Z., Qian, C., Abe, S., Arai, K., 2011. The origin of natural tetraploid loach *Misgurnus anguillicaudatus* (Teleostei: Cobitidae) inferred from meiotic chromosome configurations. *Genetica* 139, 805 – 811.
- Ludwig, A., Belfiore, N.M., Pitra, C., Svirsky, V., Jenneckens, I., 2001. Genome duplication events and functional reduction of ploidy levels in sturgeon (*Acipenser*, *Huso* and *Scaphirhynchus*). *Genetics* 158, 1203–1215.
- Manca, R., Glomski, C.A., Pica, A., 2019. Hematopoietic stem cells debut in embryonic lymphomyeloid tissues in elasmobranch. *Eur. J. Histochem.* 63, 178–187.
- Mattisson, A., Fänge, R., 1982. The cellular structure of the Leydig organ in the shark, *Etmopterus spinax* (L.). *The Biological Bulletin* 162, 182–194.
- Maxime, V., 2008. The physiology of triploid fish: current knowledge and comparison with diploid fish. *Fish. Fish.* 9, 67–78.
- Palikova, M., Mares, J., Jirasek, J., 1999. Characteristics of leukocytes and thrombocytes of selected sturgeon species from intensive breeding. *Acta Vet. BRNO* 68, 259–264.
- Paquette, C.E., Kent, M.L., Peterson, T.S., Wang, R., Dashwood, R.H., Löhr, C.V., 2015. Immunohistochemical characterization of Intestinal Neoplasia in Zebrafish (*Danio rerio*) indicates epithelial origin. *Dis. Aquat. Org.* 116, 191–1917.
- Peng, Z., Ludwig, A., Wang, D., Diogo, R., Wei, Q., He, S., 2007. Age and biogeography of major clades in sturgeons and paddlefishes (Pisces: Acipenseriformes). *Mol. Phylogenet. Evol.* 42, 854–862.
- Petermann, A.E., Petrie-Hanson, L., 2006. Ontogeny of American paddlefish lymphoid tissue. *J. Fish Biol.* 69, 72–88.
- Petrie-Hanson, L., Petermann, A.E., 2005. American paddlefish leukocytes demonstrate mammalian-like cytochemical staining characteristics in lymphoid tissues. *J. Fish Biol.* 66, 1101–1115.
- Piackova, V., Palikova, M., Zuskova, E., Flajshans, M., 2014. Stanovení diferenciálního počtu leukocytů ryb. Edition of Methods, FFPW USB, Vodnany, No.160, 65 pp. (in Czech)
- Piferrer, F., Beaumont, A., Falguiere, J.C., Flajshans, M., Haffray, P., Colombo, L., 2009. Polyploid fish and shellfish: Production, biology and applications to aquaculture for performance improvement and genetical containment. *Aquaculture* 293,125–156.
- Ramos-Vara, J.A., 2005. Technical aspects of immunohistochemistry. *Vet. Pathol.* 42, 405–426.
- Ramos-Vara, J.A., Miller, M.A., 2014. Antigens and antibodies getalong: Revisiting the technical aspects of immunohistochemistry – the red, brown and blue technique. *Vet. Pathol.* 51, 42–87.
- Ramos-Vara, J.A., Kiupel, M., Baszler, T., Bliven, L., Brodersen, B., Chelack, B., Czub, S., Del Piero, F., Dial, S., Ehrhart, E.J., Graham, T., Manning, L., Paulsen, D., Valli, V.E., West, K., 2008. Suggested guidelines for immunohistochemical techniques in veterinary diagnostic laboratories. *Journal of Veterinary Diagnosis and Investigation* 20, 393–413.
- Roberts, R.J., Ellis, A.E., 2012. The Anatomy and Physiology of Teleosts. In: Roberts, R.J. et al. (Eds), *Fish pathology*. Fourth edition, Wiley-Blackwell, pp. 17–61.
- Ruiz, F.S., Alessi, A.C., Chagas, C.A., Pinto, G.A., Vassallo, J., 2005. Immunohistochemistry in diagnostic veterinary pathology: a critical review. *Jornal Brasileiro de Patologia e Medicina Laboratorial* 41, 263–270.
- Salkova, E., Flajshans, M., 2016. The first finding of Hassall's corpuscles in the thymi of cultured sturgeons. *Vet. Med.* 61, 464–466.

- Salkova, E., Flajshans, M., Steinbach, C., 2020. Immunohistochemical mapping of thymic microenvironment in sterlet (*Acipenser ruthenus*). *Vet. Med.* 65, 301–308.
- Scharrer, E., 1944. The histology of the meningeal myeloid tissue in ganoids *Amia* and *Lepisosteus*. *The Anatomical Record.* 88: 291–297.
- Smith, E.M., Gregory, T., 2009. Patterns of genome size diversity in the ray-finned fishes. *Hydrobiologia* 625, 1–25.
- Svobodova, Z., Pravda, D., Modra, H., 2012. Unified methods of fish haematological investigations. RIFCH Vodnany, Edition of Methods, No. 122. 29 pp. (in Czech)
- Tavassoli, M., 1986. Bone marrow in boneless fish: lessons of evolution. *Med. Hypotheses* 20, 9–15.
- Tiwary, B.K., Kirubakaran, R., Ray, A.K., 2004. The biology of triploid fish. Review in *Fish Biology and Fisheries* 14, 391–402.
- Volff, J. N., 2005. Genome evolution and biodiversity in teleost fish. *Heredity* 94, 280–294.
- Wlasow, T., Fopp-Bayat, D., 2011. The effect of thermal shock on morphological characteristics of blood cells in Siberian sturgeon (*Acipenser baerii*) triploids. *Acta Vet. BRNO* 80, 215–218.
- Yasumoto, S., Koga, D., Tanaka, K., Kondo, M., Takahashi, Y., 2015. Histopathological and immunohistochemical studies of gonadal undifferentiated carcinoma in common carp *Cyprinus carpio*. *Fish Pathol.* 50, 53–59.
- Zexia, G., Weimin, W., Yi, Y., Abbas, K., Dapeng, L., Guiwei, Z., Diana, J.S., 2007. Morphological studies of peripheral blood cells of the Chinese sturgeon, *Acipenser sinensis*. *Fish Physiol. Biochem.* 33, 213–222.



## **CHAPTER 2**

### **THE FIRST FINDING OF HASSALL'S CORPUSCLES IN THE THYMI OF CULTURED STURGEONS**

---

Salkova, E., Flajshans, M., 2016. The first finding of Hassall's corpuscles in the thymi of cultured sturgeons. *Vet. Med.* 61, 464–466.

According to the publishing agreement between the authors and publisher, it is allowed to include the paper in this Ph.D. thesis.

[https://doi: 10.17221/247/2015-VETMED](https://doi.org/10.17221/247/2015-VETMED)

My share of this work was 70%





## The first finding of Hassall's corpuscles in the thymi of cultured sturgeons

E. SALKOVA, M. FLAJSHANS

South Bohemian Research Center of Aquaculture and Biodiversity of Hydrocenoses,  
Faculty of Fisheries and Protection of Waters, University of South Bohemia in Ceske Budejovice,  
Ceske Budejovice, Czech Republic

**ABSTRACT:** Histological examination of thymi from juvenile *Acipenser ruthenus* and *Acipenser brevirostrum* after haematoxylin and eosin staining revealed the presence of Hassall's corpuscles, in a scattered distribution within the thymic medulla in two of seven, and one of nine examined specimens, respectively. Morphologically, the Hassall's corpuscles were of the juvenile and premature type and no degenerative changes were seen.

**Keywords:** *Acipenser ruthenus*; *Acipenser brevirostrum*; histology; thymus

The thymus in fish is a paired lymphoepithelial organ lying on the upper inside edge of the operculum, just beneath the cuboidal or flat epithelium covering the branchial cavity (Roberts and Ellis 2012). Embryologically, the thymus is derived from the third pharyngeal pouch. Thymi in sturgeons persist until the fish reach sexual maturity. Later, these undergo age-related atrophy (Fange 1986).

Histologically, the thymus is lobulated and organised in the outer cortex enclosing the central medulla (Petrie-Hanson and Peterman 2005). A diversity of different cell types is found within the thymus. The cortex is predominantly composed of closely packed lymphocytes. The medulla is composed of sparsely organised lymphocytes, macrophages, reticular cells and Hassall's corpuscles that have a disperse distribution (Fange 1986; Petrie-Hanson and Peterman 2005; Peterman and Petrie-Hanson 2006).

Hassall's corpuscles are components of the non-lymphocytic microenvironment of the thymic medulla. Histologically, the corpuscles are rounded or spherical epithelial structures varying in size. They are composed of eosinophilic reticuloepithelial cells, often concentrically arranged. The central part of the corpuscle may undergo the process of degeneration. Regressive changes including hyalin-

isation, calcification and cyst formation can also be observed. The number of Hassall's corpuscles may vary according to the age, the course of disease or the presence of stress (Furukawa 2012). Mammalian Hassall's corpuscles may be divided into four types according to their morphology: juvenile, premature, mature and senescent (advanced) type (Asghar et al. 2012). The juvenile type represents the early developmental stage of Hassall's corpuscles, in which one or two reticuloepithelial cells are arranged in a cluster. The premature stage is represented by small groups of hypertrophic cells showing early processes of keratinisation, but without the evident tendency to concentric arrangement, or a flattened appearance. In the mature type, the reticuloepithelial cells are flattened, and concentrically arranged around the mixture of keratin and degenerated lymphocytes and macrophages. In the advanced stage, Hassall's corpuscles demonstrate varying degrees of material deposition both in the centre as well as on the periphery of the corpuscle. The shape of the corpuscle seems to be distorted, and in some cases the tendency of corpuscles to fuse is evident. Regressive changes including cystic space formation, and pronounced hyalinisation or calcification are often present (Asghar et al. 2012).

Supported by the MEYS of the CR, Project CENAKVA (Project No. CZ.1.05/2.1.00/01.0024), Project CENAKVA II under the NPU I program (Project No. LO1205), and GACR (Project No.14-02940S).

doi: 10.17221/247/2015-VETMED

Table 1. Length, weight and age characteristics of histologically examined fish

Species	Total length (mm) range/median	Total weight (g) range/median	Age (months) range/median	No. of specimens
<i>Acipenser ruthenus</i>	136–480/180	9–180/28	6–19/14.5	7
<i>Acipenser brevirostrum</i>	100–140/120	3–12/6.5	2.5–11/6.25	9

## MATERIAL AND METHODS

The study material comprised seven juvenile functionally diploid (2n) specimens of *Acipenser ruthenus* and nine juvenile functionally hexaploid (6n) specimens of *Acipenser brevirostrum* originating from the hatchery of the Faculty of Fisheries and Protection of Waters, University of South Bohemia, Czech Republic. Length and weight characteristics of the examined fish are given in Table 1. The study was carried out in accordance with the Czech Law No. 246/1992 regarding animal welfare. Protocols underwent an ethical review process at the University of South Bohemia animal care committee (PP3/FROV/2012; in Czech). Fish were sacrificed with all efforts made to minimise suffering. Clove oil in the amount of 30–40 mg/l was used for anaesthesia; subsequently, a double dose was used for euthanasia. Whole specimens were fixed in 10% neutral-buffered formalin. After fixation, specimens were cut vertically, and in three cases horizontally as well. The tissue was embedded in paraffin, conventionally processed and stained with haematoxylin and eosin (H-E), Giemsa and periodic acid-Schiff staining. Alcian blue staining was done in one case, and mucin staining was performed in four cases. Obtained slides were inspected under an

Olympus BHS microscope, recorded with a 3CCD Sony DXC-9100P colour camera and processed in Olympus MicroImage v. 4.0 software.

## RESULTS

Thymi were found in sixteen specimens, and were examined histologically. The thymi were lobulated and were composed of the outer cortex and the inner medulla. In two of the seven specimens of *Acipenser ruthenus* (one 6-month-old and one 14-month-old sterlet), and one of nine specimens of *Acipenser brevirostrum* (8.5-month-old), Hassall's corpuscles were found, dispersed within the thymic medulla. Hassall's corpuscles were round or oval in shape and eosinophilic in H-E staining (Figures 1 and 2). Their size, i.e. diameter of round corpuscles and the maximum and minimum diameters of the oval ones was 36  $\mu\text{m}$ , and 20  $\mu\text{m} \times 78 \mu\text{m}$ , respectively. The cytoplasm was slightly granular. According to the mammalian criteria for morphological assessment, only the juvenile and the premature type of Hassall's corpuscles were observed. They consisted of small clusters of reticuloepithelial cells without signs of keratinisation and flattening, or clusters of hypertrophic reticuloepithelial cells with early

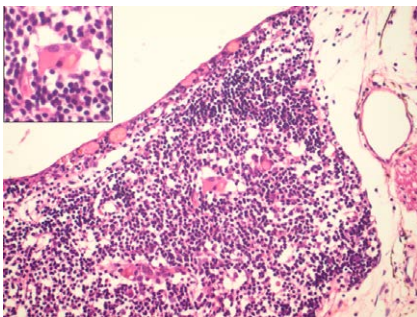


Figure 1. Histological section of the thymus of the juvenile sterlet, *Acipenser ruthenus* after staining with haematoxylin-eosin, under  $\times 400$  magnification. Hassall's corpuscle is presented as an inset in the figure

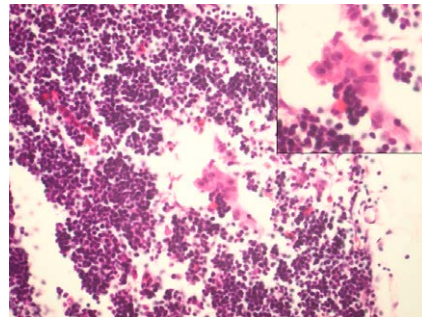


Figure 2. Histological section of the thymus of juvenile *Acipenser brevirostrum* after staining with haematoxylin-eosin, under  $\times 400$  magnification. Hassall's corpuscle is presented as an inset in the figure

stages of keratinisation. Mucin staining was negative in the premature stage of Hassall's corpuscles. No tendency of corpuscles to fuse was found; the Hassall's corpuscles did not exhibit any degenerative changes.

## DISCUSSION

Bearing the name of the British physician Arthur Hill Hassall, who first described these structures in 1849 in the thymi of children (Hassall 1849), Hassall's corpuscles are commonly found in the thymic medulla in different animals. They were described in lungfish (Mohammad et al. 2007), in teleosts (Bowden et al. 2005) and in mammals (Furukawa et al. 2012).

Among acipenseriform fish, they were reported only in American paddlefish *Polyodon spathula* (Walbaum 1792) (Petrie-Hanson and Peterman 2005). Histological examination of the lymphoid tissue was performed on the specimens at the age of 18 months post-hatch. Whorls of epithelial cells and early Hassall's corpuscles were noted within *Polyodon* thymi (Petrie-Hanson and Peterman 2005).

Sturgeon lymphoid organs were described by Fange (1986). His study included 20 specimens of the Pacific white sturgeon (*Acipenser transmontanus*), with body weights ranging from 60.8 to 33 200 g. Some of the specimens were caught in the wild. Hatchery-reared young hybrid sturgeons (*Huso huso* × *Acipenser ruthenus*), were also included in the study. Additionally, thymi were found and examined in three specimens of *Acipenser transmontanus* (body weights varying between 179 and 33 200 g, ages varying between half a year and two and a half years, one specimen was caught in the wild and was of unknown age) and Hassall's corpuscles were not found. Thymic atrophy related to age was noted in one specimen.

Our observation in juvenile *Acipenser ruthenus* and *Acipenser brevirostrum* seems to be the first description of Hassall's corpuscles in sturgeons. Juvenile and premature stages of Hassall's corpuscles were found. We propose to extend the histological and immunohistochemical examinations of these thymi.

## Acknowledgement

The authors wish to acknowledge the technical assistance of Mrs Jindriška Prochazkova from the Department of Pathology and Molecular Medicine, 2<sup>nd</sup> Medical Faculty, Charles University in Prague.

## REFERENCES

- Asgar A, Yunus MS, Faruqi AN (2012): Polymorphism of Hassall's corpuscles in thymus of human fetuses. *International Journal of Applied and Basic Medical Research* 2, 7–10.
- Bowden TJ, Cook P, Rambout JHWM (2005): Development and function of the thymus in teleosts. *Fish and Shellfish Immunology* 19, 413–427.
- Fange R (1986): Lymphoid organs in sturgeons (Acipenseridae). *Veterinary Immunology and Immunopathology* 12, 153–161.
- Furukawa S, Wingenfeld L, Morita S, Takay A, Nakagawa T, Sakaguchi I, Matsuda W, Nishi K (2012): Histochemical and morphological characteristics of the Hassall's corpuscles. The stress affects involution of the ectopic intra-thyroidal and the normal position thymus and morphological changes of the Hassall's corpuscles. *Journal of Forensic Research* 2012, 3–9.
- Hassall AH (1849): The microscopic anatomy of the human body. In: *Health and Disease*. Samuel Highley, London. 281 pp.
- Mohammad MG, Chilmontczyk S, Birch D, Aladaileh S, Raftos D, Joss J (2007): Anatomy and cytology of the thymus in juvenile Australian lungfish, *Neoceratodus forsteri*. *Journal of Anatomy* 211, 784–797.
- Peterman AE, Petrie-Hanson L (2006): Ontogeny of American paddlefish lymphoid tissue. *Journal of Fish Biology* 69, 72–88.
- Petrie-Hanson L, Peterman AE (2005): American paddlefish leukocytes demonstrate mammalian-like cytochemical staining characteristics in lymphoid tissues. *Journal of Fish Biology* 66, 1101–1115.
- Roberts RJ, Ellis AE (2012): 2. The anatomy and physiology of teleosts. In: Roberts RJ (ed.): *Fish Pathology*. 4<sup>th</sup> edn. Wiley-Blackwell, Oxford. 17–62.

Received: 2015–11–15

Accepted after correction: 2016–06–10

Corresponding Author:

Eva Salkova, University of South Bohemia in Ceske Budejovice, Faculty of Fisheries and Protection of Waters, South Bohemian Research Center of Aquaculture and Biodiversity of Hydrocenoses, Zatisi 728/II, 389 25 Vodnany, Czech Republic  
E-mail: salkoe00@frov.jcu.cz



## CHAPTER 3

### IMMUNOHISTOCHEMICAL MAPPING OF THYMIC MICROENVIRONMENT IN STERLET (*ACIPENSER RUTHENUS*)

---

Salkova, E., Flajshans, M., Steinbach, C., 2020. Immunohistochemical mapping of thymic microenvironment in sterlet (*Acipenser ruthenus*). Vet. Med. 65, 301–308.

According to the publishing agreement between the authors and publisher, it is allowed to include the paper in this Ph.D. thesis.

<https://doi.org/10.17221/181/2019-VETMED>

My share on this work was 70%.



## Immunohistochemical mapping of thymic microenvironment in sterlet (*Acipenser ruthenus*)

EVA SALKOVA\*, MARTIN FLAJSHANS, CHRISTOPH STEINBACH

South Bohemian Research Center of Aquaculture and Biodiversity of Hydrocenoses, Faculty of Fisheries and Protection of Waters, University of South Bohemia in Ceske Budejovice, Ceske Budejovice, Czech Republic

\*Corresponding author: [pat.vesela.eva@email.cz](mailto:pat.vesela.eva@email.cz)

**Citation:** Salkova E, Flajshans M, Steinbach C (2020): Immunohistochemical mapping of thymic microenvironment in sterlet (*Acipenser ruthenus*). Vet Med-Czech 65, 301–308.

**Abstract:** In this study, we describe the immunohistochemical characterisation of the thymus, the main lymphoid organ, in sturgeon. The wide range cytokeratin, vimentin, S-100 protein, LCA (CD45) and CD3 were selected as the immunohistochemical markers to map the thymus in juvenile sterlet (*Acipenser ruthenus*). The epithelial cells and Hassall's corpuscles were labelled with a wide range cytokeratin. The fibroblasts and connective tissue within the thin fibrous capsule on the thymic surface expressed vimentin positivity. The stromal reticular cells were S-100 protein positive. The Leukocyte Common Antigen LCA (CD45) was negative on the thymic lymphocytes. The CD3 was negative on the thymic lymphocytes with cross-reactivity on the non-targeted structures. In conclusion, the commercially available antibodies against the wide range cytokeratin, vimentin and S-100 protein can be used to differentiate components of the sturgeon thymus, while the LCA (CD45) and CD3 application failed. We suggest that further studies are needed to generate fish specific antibodies.

**Keywords:** CD3; Hassall's corpuscles; LCA (CD45); S-100 protein; vimentin; wide range cytokeratin

The thymus is considered as the primary lymphoid organ in sturgeons, *Acipenseridae* (Petrie-Hanson and Peterman 2005; Peterman and Petrie-Hanson 2006). The thymus is a paired lymphoepithelial organ situated on the upper inside edge of the operculum in close proximity to the branchial cavity and pharyngeal epithelium (Bowden et al. 2005; Salkova and Flajshans 2016). Thymi persist until the fish reach sexual maturity, later the thymus undergoes age-related atrophy. From an evolutionary perspective, the interaction of three embryonic germ layers (ectoderm, endoderm and mesoderm) takes place during the thymic development (Bowden et al. 2005). Histologically,

the surface of the thymus is covered with a fine fibrous capsule. The thymus is lobulated and consists of an outer cortex and the inner medulla, with a diverse range of cell types within its microenvironment (Salkova and Flajshans 2016). The epithelial cells constitute a fine epithelial intra-thymic network (Mohammad et al. 2007; Gradil et al. 2014), while closely packed lymphocytes dominate the cortex. The medulla consists of sparsely organised lymphocytes, macrophages, reticular cells, fibroblasts and dispersedly distributed Hassall's corpuscles (Bowden et al. 2005; Petrie-Hanson and Peterman 2005; Peterman and Petrie-Hanson 2006; Salkova and Flajshans 2016).

Supported in parts by the Ministry of Education, Youth and Sports of the Czech Republic projects CENAKVA (LM2018099), Biodiversity (CZ.02.1.01/0.0/0.0/16\_025/0007370) and PROFISH (CZ.02.1.01/0.0/0.0/16\_019/0000869).

Currently, few studies have reported histological and ultrastructural examinations of the thymus in acipenserid fishes (Petrie-Hanson and Peterman 2005; Peterman and Petrie-Hanson 2006; Gradil et al. 2014; Salkova and Flajshans 2016). To the best of our knowledge, there is no literature concerning the immunohistochemical (IHC) mapping of the thymic microenvironment in sturgeons.

Immunohistochemistry is a method which detects expression of markers in tissues and organs by applying mono- or polyclonal antibodies against antigens (Ramos-Vara et al. 2008). Currently, Mohammad et al. (2007) have studied the application of IHC on the thymus of Australian lungfish, *Neoceratodus forsteri*. They described the immunohistochemical examination of the cytoskeletal proteins (cytokeratins, desmin, vimentin, actin and tubulin) in the thymic epithelial cells and found that the positivity of each antibody differed depending on the location within the thymus (capsule, cortex, medulla). The study helped to define seven categories of thymic epithelial cells in lungfish.

In the present study, a wide spectrum of markers was examined in order to characterise the specific cell types located within the thymus of sterlet (*Acipenser ruthenus*). This immunohistochemical study followed the study of Salkova and Flajshans (2016), describing a histological investigation of the thymus and Hassall's corpuscle in sturgeon. Moreover, this study examined application of commercially available antibodies in ichthyological practice. We applied antibodies against markers representing the main components of the thymic structure: a wide range cytokeratin to map the epithelial components, vimentin to highlight the mesenchymal components, the S-100 protein to map the neuroectodermal constituents, and the LCA (CD45) and CD3 to map the thymic lymphoid elements.

## MATERIAL AND METHODS

### Fish

A six-month-old functionally diploid (2n) specimen of sterlet (TL = 14 cm, BW = 28 g) was obtained from the hatchery of the Faculty of Fisheries and Protection of Waters (FFPW), University of South Bohemia (USB), Czech Republic for the histological and immunohistochemical examination. This

study was conducted in accordance with Czech Law No. 246/1992 on animal welfare. The Institutional Animal Care and Use Committee (IACUC) of the University of South Bohemia, Faculty of Fisheries and Protection of Waters (USB FFPW) in Vodňany, supervised and approved the scientific protocol. The USB FFPW has approval from the Ministry of Agriculture of the Czech Republic for the handling and usage of experimental animals, Ref. No. 16OZ15759/2013-17214. Clove oil (30–40 mg/l) was used for the anaesthesia, while a double dose was used for the euthanasia.

### Histological preparations

The whole specimen was fixed in 10% neutral-buffered formalin. After fixation, the sterlet was vertically cut. The tissues were embedded in paraffin, conventionally processed, and stained with haematoxylin and eosin (HE). The obtained slides were inspected under an Olympus BHS microscope, and a proper paraffin block containing the thymus was chosen for the IHC examination. The identification of Hassall's corpuscle in the thymus was based on the description of Salkova and Flajshans (2016). Tissue sections with a thickness of 4 µm were used for the IHC.

### Studied antibodies

The wide range cytokeratin (clone KL1), S-100 protein, vimentin, LCA (CD45), CD3 were used to map the components of the thymic microenvironment. The antibodies used in this study and their characteristics are summarised in Table 1. All the antibodies have been routinely used in human medicine, of mammalian origin and specifically designed to target antigens located on human cells.

### Immunohistochemical examination

The immunohistochemical examination followed specific protocols developed by investigators and antibody suppliers, so that the heat-induced antigen retrieval procedure (LCA, CD3), or direct antibody application with endogenous enzymatic blockage (cytokeratin, vimentin, S-100 protein) were used. Each antibody dilution was performed individu-



<https://doi.org/10.17221/181/2019-VETMED>

Table 1. The characteristics of the selected antibodies applied to the thymus of the sterlet (*Acipenser ruthenus*)

Antibody	Supplier	Clone	Antigen source	Dilution	Isotype control
Wide range cytokeratin	Immunotech	KL1	polyclonal	1 : 100	IgG <sub>1</sub>
Vimentin	Roche	V9	monoclonal mouse	RTU	IgG <sub>2a</sub> /K
S-100	Roche	4C4.9	monoclonal mouse	RTU	IgG/K
Leukocytes common antigen LCA (CD45)	Dako	2B11 + PD7/26	monoclonal mouse	1 : 400	IgG <sub>1</sub> /K
CD3	Dako	F7.2.38	monoclonal mouse	1 : 100	IgG <sub>1</sub> /K

RTU = ready to use

ally and was adjusted in accordance with the supplier guidelines and laboratory expertise (Table 1). The application of the primary antibody was followed by the overnight incubation in a humidity chamber at 4 °C. A detection system was used to bind with the primary antibody. The antigen-antibody complex was visualised using chromogen 3-3' diaminobenzidine tetrahydrochloride (DAB). Therefore, a positive result created a brown end-product. Harris' haematoxylin was used to perform the nuclear counterstaining.

Human tissues, (including the tonsil and appendix) that are known to be reactive for the investigated marker, were used as positive controls. The internal tissue control was conducted while evaluating the immunohistochemical slides. The results of the immunostaining were concluded as either negative or positive. The staining pattern (nuclear, cytoplasmic and membrane) was described for each marker. The intensity of the positive reaction was evaluated in accordance with the three-degree scale: weak (+), moderate (++), and strong (+++) positivity. Any other reactions (atypical or cross-reaction) were documented. The slides were evaluated independently by two observers (ES, CS).

## RESULTS

The histological examination revealed a lobulated thymus, covered by a fine fibrous capsule on the surface, and consisted of an outer cortex and inner medulla.

### Wide range cytokeratin

Wide range cytokeratin labelled the epithelial components: a fine network of epithelial cells and

Hassall's corpuscles revealed moderate membranous positivity.

A positive internal control was approved on the flat/cuboidal epithelium covering the branchial cavity, on the squamous epithelium in the oral cavity and on the stratified squamous epithelium of the skin (Figure 1A).

### Vimentin

Vimentin labelled the fine fibrous capsule on the thymic surface with strong cytoplasmic intensity (Figure 1B). A positive internal control was observed on the basement membrane of the skin.

### S-100 protein

The S-100 protein revealed a strong cytoplasmic positivity on the stromal reticular cells within the cortex and medulla (Figure 1C). A positive internal control was observed on the adjacent peripheral nerve and the peripheral ganglion, i.e., the nerve fibres revealed a strong cytoplasmic positivity, whereas the neurons, composing the peripheral ganglion, were negative.

A positive internal control was found on the afferent nerve fibres accompanying the taste buds in the oral cavity.

### LCA (CD45)

The LCA (CD45) was negative on the targeted structures, i.e., the thymic lymphoid elements were negative. Simultaneously, negativity was noticed on the leukocytes located within the connective tissue adjacent to the skin and leukocytes within the gills.

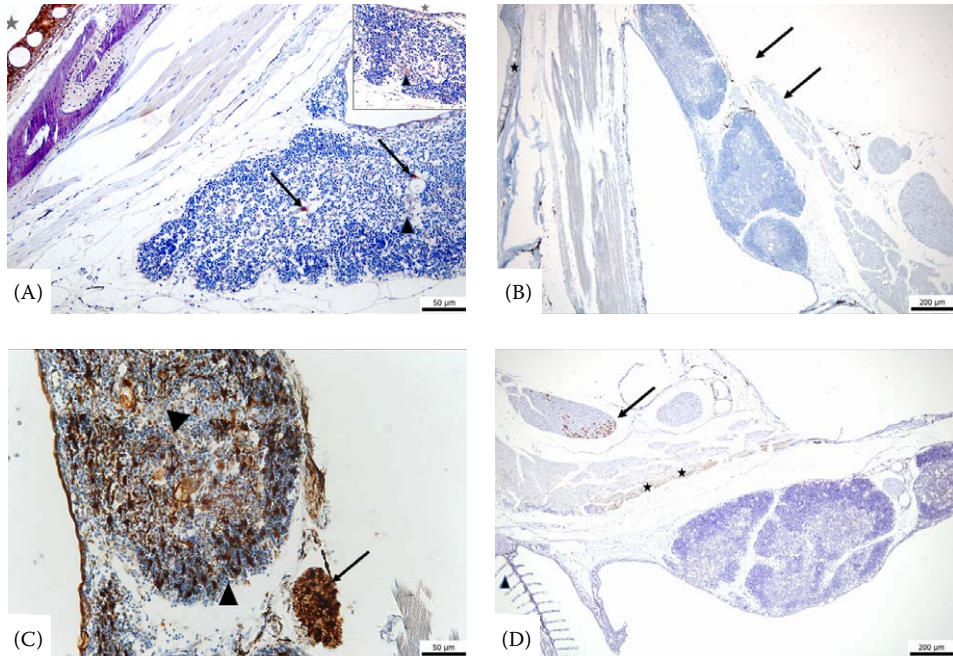


Figure 1. The immunohistochemical examination of the thymus in the sterlet (*Acipenser ruthenus*). (A) Wide range cytokeratin, clone KL 1 (magnification  $\times 40$ ; scale bar 50  $\mu\text{m}$ ). The fine network of epithelial cells revealed moderate membranous positivity (arrowhead); the fine network is presented as an inset in the figure in the upper right corner. Hassall's corpuscles reacted with strong positivity (arrows). A positive internal control was observed on the epidermis and on the flat/cuboidal epithelium covering the adjacent branchial cavity (star). (B) Vimentin (magnification  $\times 20$ ; scale bar 200  $\mu\text{m}$ ). The thin fibrous capsule on the thymic surface revealed strong cytoplasmic positivity (indicated by the arrows). A positive internal control was observed on thin basement membrane in the skin (star). (C) S-100 protein (magnification  $\times 60$ ; scale bar 50  $\mu\text{m}$ ). The stromal reticular cells within the cortex and medulla revealed strong cytoplasmic positivity (arrowheads). A positive internal control was presented on the adjacent peripheral nerve (positivity on nerve fibres) located in close proximity to the thymus (arrow). (D) CD3 (magnification  $\times 20$ ; scale bar 200  $\mu\text{m}$ ). The thymic lymphocytes were negative. A cross-reaction was noticed on the adjacent non-targeted structures: the stars pointed at the muscular fibres, the arrowhead at the supportive tissue in the gill lamellae, the arrow at the neurons within the peripheral ganglion

### CD3

The CD3 was negative on the targeted thymic lymphocytes. The cross-reactivity with an altered staining pattern (cytoplasmic instead of membranous positivity) was revealed on the non-targeted tissues including the neurons in the peripheral ganglion, the striated muscle fibres and myocardium, the scattered developmental stages of granulocytes within the meningeal myeloid tissue (Figure 1D).

### DISCUSSION

Cytokeratins are intermediate filament proteins that contribute to the cytoskeleton of epithelial cells. There are two large families of cytokeratins, acidic and basic cytokeratins, but all contain the same basic domain (Schaffeld et al. 2001). Cytokeratins are expressed in epithelial cells. According to the knowledge from human research, individual human cytokeratins are numbered 1 to 20. Anti-cytokeratin antibody applications in ich-

<https://doi.org/10.17221/181/2019-VETMED>

thyology is well documented. Generally, commercially available antibodies originally produced for human medicine have been applied in fish tissues. Several studies are mapping the occurrence of cytokeratins in different types of epithelial cells under physiological conditions, i.e., Schmitz (1998) tested the polyclonal anti-keratin antibody in the notochord cells of shortnose sturgeon (*Acipenser brevirostrum*), West African lungfish (*Protopterus annectens*) and yellow perch (*Perca flavescens*). Garcia et al. (2005) performed a study to analyse the keratin occurrence in carp and goldfish (*Carassius auratus*) within different epithelial tissues (skin, fin tip, gill, liver) and compared the results with zebrafish (*Danio rerio*) and rainbow trout (*Oncorhynchus mykiss*). Ng et al. (2005) prepared a study concerning the formation of the digestive system in zebrafish using an anti-pan-cytokeratin antibody to highlight the intestinal epithelium morphogenesis. Bunton (1993) tested the anti-cytokeratin antibodies (cytokeratin AE, MAK-6 and CAM 5.2) in multiple fish tissues in striped bass (*Morone saxatilis*) and medaka (*Oryzias latipes*). Moreover, there are studies describing the anti-cytokeratin antibody application to perform a tumour identification and classification, i.e., Iaria et al. (2019) applied the anti-cytokeratin antibody in bream (*Abramis brama*) to confirm papilloma. Yasumoto et al. (2015) performed an immunohistochemical study in common carp (*Cyprinus carpio*) using a spectrum of antibodies including anti-pan-cytokeratin to perform the diagnosis of undifferentiated gonadal carcinoma. Only a small number of studies described the application of fish-specific antibodies designed and produced by the scientist themselves [Pan et al. (2000) in stomachless fishes]. The application of fish-specific antibodies is thought to avoid the negativity/non-reactivity or cross-reaction, respectively (Ramos-Vara et al. 2008).

In this study, we have shown that the fine network of thymic epithelial cell and juvenile and premature Hassall's corpuscles were cytokeratin positive. Our finding was, thus, in agreement with the immunohistochemical studies performed on lungfish thymi (Mohammad et al. 2007) and human thymi (Raica et al. 2006).

Vimentin is an intermediate-sized filament and helps to constitute the main part of the cellular cytoskeleton (Herrmann et al. 1996). Among mammals, birds, reptiles, amphibians and teleost fishes,

vimentin shares an extensive amino acid sequence homology (Schaffeld et al. 2001). Moreover, despite the highly conserved primary structure, the expression pattern of vimentin in fish is different than in mammals (Herrmann et al. 1996). Reportedly, the environmental temperature is an important principle for the fine primary protein structure setting (Herrmann et al. 1996; Schaffeld et al. 2001). Vimentin reacts with cytoplasmic positivity and is reported to be expressed in most cells of mesenchymal origin, including fibroblasts, endothelial cells, melanocytes, smooth muscle cells and is regarded to be a sensitive and specific marker for mesenchymal derivation and differentiation (Schaffeld et al. 2001; Iaria et al. 2019). Vimentin reacts with cytoplasmic positivity. Iaria et al. (2019) applied an anti-vimentin antibody to identify tumours in fish: vimentin positivity obtained in sand steenbras helped to perform the diagnosis of a dermal fibroma. In contrast, vimentin negativity contributed to conclude the diagnosis of an undifferentiated carcinoma in carp (Yasumoto et al. 2015). In this study, the thin fibrous capsule on the thymic surface reacted positively, just as the other structures of mesenchymal origin (basement membrane of the skin).

The S-100 proteins play an important role in cell physiology involving various cellular activities such as signal transduction, cell differentiation, gene transcription, calcium homeostasis and cell cycle progression (Fonseca et al. 2011). The S-100 protein family is comprised of 20 members (primarily described in humans), they are highly similar in structure, but exhibit distinctive patterns of cell and tissue distribution (Fonseca et al. 2011). The S-100 protein results in cytoplasmic positivity and is reportedly expressed in cells of neuroectodermal origin (Sandulescu et al. 2011; Iaria et al. 2019), as well as on the antigen-presenting cells, such as stromal reticular cells within the thymus (Raica et al. 2006). Application of the antibody against the S-100 protein contributed to the diagnosis of melanoma in an *Xiphophorus* hybrid and schwannoma in a crucian carp (*Carassius carassius*) (Iaria et al. 2019). In our study, the thymic stromal reticular cells revealed strong cytoplasmic S-100 protein positivity. However, Raica et al. (2006) described S-100 protein positivity in human Hassall's corpuscles, while, in our study, no positivity was expressed in Hassall's corpuscles. The different antibody clone application, heat-induced

epitope retrieval, incubation times or different developmental stages in Hassall's corpuscles might explain the conflicting results (Ramos-Vara et al. 2008). Moreover, no background cross-reactivity was observed in the abovementioned markers in the sturgeon tissue.

The leukocyte common antigen (LCA, CD45), a transmembrane protein tyrosine phosphatase, is expressed in haematopoietic cells. LCA plays an important role in the maturation and differentiation of B- and T-lymphocytes, T-cells without LCA cannot respond to the antigen. In mammals, LCA labels the thymic lymphocytes (Kurtin and Pinkus 1985). LCA can be expressed in different isoforms depending on the cell type, the state of activation and differentiation (Diaz del Pozo et al. 2000). The CD45 gene structure in fugu (*Takifugu rubripes*) seems to be similar to the human CD45 gene, i.e., similar exon/intron organisation. Some differences were noticed in the 5' end structure in the fugu, however, the CD45 gene in the fugu is smaller than the human gene due to the smaller size of the introns in the fugu (Diaz del Pozo et al. 2000). Holmes (2005) pointed out that the polymorphic variants result in a high number of variations in the coding region, which was evident in mammals and hagfish. When performing the LCA examination, a positive result is considered as membranous positivity.

CD3 represents a marker specific for T-lymphocytes, and in mammals, reacts positively with the early developmental stages of the thymocytes (Mason et al. 1989). CD3 is an essential component of the T-cell receptor (TCR) complex antigen. TCR is expressed as a multisubunit membrane complex and CD3 components are responsible for coupling the antigen ligation events with the intracellular signalling pathway (Alabyev et al. 2000). Most of the commercially available antibodies target the CD3 component. The CD3 component was analysed and sequenced in sterlet (Alabyev et al. 2000), in rainbow trout (Boardman et al. 2012) and Japanese pufferfish (*Takifugu rubripes*) (Araki et al. 2005). Some studies have suggested particular sequence conservation among fish species and some homology with mammalian CD3 (Boardman et al. 2012). Still, a high transcript heterogeneity is demonstrated in the sterlet CD3 (Alabyev et al. 2000). When performing the IHC in the CD3, the CD3 results in membranous positivity. In our study, no reactivity of the examined and targeted lymphoid

markers (LCA, CD3) was detected. Additionally, a cross-reaction with different staining pattern (cytoplasmic instead of membranous positivity) was present while examining the CD3. The LCA and CD3, thus, proved ineffective at staining the cells of lymphoid origin in sterlet. The structural polymorphism and heterogeneity may represent the main reasons for the unsuccessful IHC examination of the lymphoid markers (LCA and CD3) in the sterlet. Consequently, and naturally, further research is required to design sturgeon specific LCA and CD3 antibodies (Ramos-Vara et al. 2008).

The immunohistochemical examination was performed using monoclonal antibodies (vimentin, S-100 protein, LCA, CD3) and a polyclonal antibody (cytokeratin). The applied antibodies were commercially available and originally designed for human medicine. Three of the five tested antibodies (cytokeratin, vimentin, S-100 protein) brought conclusive results with the expected staining pattern (references), and no cross-reactivity was detected in the background. Positive results were obtained regardless of the origin of the monoclonal or polyclonal antibody. Therefore, these markers (cytokeratin, vimentin, S-100 protein) can be recommended for application on sturgeon.

Negative results, or non-reactivity respectively, were obtained when examining the LCA. While testing the CD3, the obtained results were negative with a cross-reactivity at the adjacent tissues. The applied antibodies were monoclonal and of mouse origin. As it was as expected, the monoclonal antibodies bound to a single epitope on an antigen, and, thus, provided high specificity (Ramos-Vara et al. 2008). The high specificity of the monoclonal antibodies and its mammalian origin might explain why negative results (or non-reactivity) were obtained when testing the lymphoid markers (LCA and CD3). Consequently, these findings support the proposal of Ramos-Vara et al. (2008) for researchers to invent and produce fish specific antibodies.

This immunohistochemical study on the thymic microenvironment in sterlet supports the previous histological findings concerning the cellular components in the thymus (Gradil et al. 2014; Salkova and Flajshans 2016). To our knowledge, this is the first study to demonstrate the application of human antibodies on a sturgeon's thymus: most of the tested antibodies (cytokeratin, vimentin, S-100 protein) were suitable for usage in stur-

<https://doi.org/10.17221/181/2019-VETMED>

geons. The non-reactivity observed in the lymphoid markers LCA and CD3 support the importance of fish specific antibody generation (Ramos-Vara et al. 2008).

### Acknowledgement

The authors wish to acknowledge the technical support of Mrs. Marcela Staňková from AeskuLab Patologie, Prague and valuable advises of Mrs. Eliška Axmannová from the Department of Pathology and Molecular Medicine, 2<sup>nd</sup> Medical Faculty and Teaching Hospital in Motol, Charles University in Prague.

### Conflict of interest

The authors declare no conflict of interest.

### REFERENCES

- Alabyev BY, Guselnikov SV, Najakshin AM, Mechetina LV, Taranin AV. CD3epsilon homologues in the chondrosteian fish *Acipenser ruthenus*. *Immunogenetics*. 2000 Oct;51(12):1012-20.
- Araki K, Suetake H, Kikuchi K, Suzuki Y. Characterization and expression analysis of CD3varepsilon and CD-3gamma/delta in fugu, *Takifugu rubripes*. *Immunogenetics*. 2005 Apr;57(1-2):158-63.
- Boardman T, Warner C, Ramirez-Gomez F, Matriciano J, Bromage E. Characterization of an anti-rainbow trout (*Oncorhynchus mykiss*) CD3ε monoclonal antibody. *Vet Immunol Immunopathol*. 2012 Jan 15;145(1-2):511-5.
- Bowden TJ, Cook P, Rombout JH. Development and function of the thymus in teleosts. *Fish Shellfish Immunol*. 2005 Nov;19(5):413-27.
- Bunton TE. The immunocytochemistry of cytokeratin in fish tissues. *Vet Pathol*. 1993 Sep;30(5):418-25.
- Diaz del Pozo E, Beverley PC, Timon M. Genomic structure and sequence of the leukocyte common antigen (CD45) from the pufferfish *Fugu rubripes* and comparison with its mammalian homologue. *Immunogenetics*. 2000 Aug; 51(10):838-46.
- Fonseca VG, Rosa J, Laize V, Gavaia PJ, Cancela ML. Identification of a new cartilage-specific S100-like protein up-regulated during endo/perichondral mineralization in gilthead seabream. *Gene Expr Patterns*. 2011 Oct;11(7): 448-55.
- Garcia DM, Bauer H, Dietz T, Schubert T, Markl J, Schaffeld M. Identification of keratins and analysis of their expression in carp and goldfish: Comparison with the zebrafish and trout keratin catalog. *Cell Tissue Res*. 2005 Nov;322(2):245-56.
- Gradil AM, Wright GM, Wadowska DW, Fast MD. Ontogeny of the immune system in Acipenserid juveniles. *Dev Comp Immunol*. 2014 Jun;44(2):303-14.
- Herrmann H, Munick MD, Brettel M, Fouquet B, Markl J. Vimentin in a cold-water fish, the rainbow trout: Highly conserved primary structure but unique assembly properties. *J Cell Sci*. 1996 Mar;109(Pt 3):569-78.
- Holmes N. CD45: all is not yet crystal clear. *Immunology*. 2005 Feb;117(2):145-55.
- Iaria C, Ieni A, Corti I, Puleio R, Brachelente C, Mazzullo G, Lanteri G. Immunohistochemical study of four fish tumors. *J Aquat Anim Health*. 2019 Mar;31(1):97-106.
- Kurtin PJ, Pinkus GS. Leukocyte common antigen – A diagnostic discriminant between hematopoietic and non-hematopoietic neoplasms in paraffin sections using monoclonal antibodies: Correlation with immunologic studies and ultrastructural localization. *Hum Pathol*. 1985 Apr;16(4):353-65.
- Mason DY, Cordell J, Brown M, Pallesen G, Ralfkiaer E, Rothbard J, Crumpton M, Gatter KC. Detection of T cells in paraffin wax embedded tissue using antibodies against a peptide sequence from the CD3 antigen. *J Clin Pathol*. 1989 Nov;42(11):1194-200.
- Mohammad MG, Chilmonczyk S, Birch D, Aladaileh S, Raftos D, Joss J. Anatomy and cytology of the thymus in juvenile Australian lungfish, *Neoceratodus forsteri*. *J Anat*. 2007 Dec;211(6):784-97.
- Ng AN, de Jong-Curtain TA, Mawdsley DJ, White SJ, Shin J, Appel B, Dong PD, Stainier DY, Heath JK. Formation of the digestive system in zebrafish: III. Intestinal epithelium morphogenesis. *Dev Biol*. 2005 Oct 1;286(1):114-35.
- Pan QS, Fang ZP, Zhao YX. Immunocytochemical identification and localization of APUD cells in the gut of seven stomachless teleost fishes. *World J Gastroenterol*. 2000 Feb;6(1):96-101.
- Peterman AE, Petrie-Hanson L. Ontogeny of American paddlefish lymphoid tissues. *J Fish Biol*. 2006 Sep;69:72-88.
- Petrie-Hanson L, Peterman AE. American paddlefish leukocytes demonstrate mammalian-like cytochemical staining characteristics in lymphoid tissues. *J Fish Biol*. 2005 Apr;66(4):1101-15.
- Ramos-Vara JA, Kiupel M, Baszler T, Bliven L, Brodersen B, Chelack B, Czub S, Del Piero F, Dial S, Ehrhart EJ, Graham T, Manning L, Paulsen D, Valli VE, West K; American Association of Veterinary Laboratory Diagnosticians Subcommittee on Standardization of Immunohistochemistry.

<https://doi.org/10.17221/181/2019-VETMED>

- Suggested guidelines for immunohistochemical techniques in veterinary diagnostic laboratories. *J Vet Diagn Invest.* 2008 Jul;20(4):393-413.
- Raica M, Encica S, Motoc A, Cimpean AM, Scridon T, Barsan M. Structural heterogeneity and immunohistochemical profile of Hassall corpuscles in normal human thymus. *Ann Anat.* 2006 Jul;188(4):345-52.
- Salkova E, Flajshans M. The first finding of Hassall's corpuscles in the thymi of cultured sturgeons. *Vet Med-Czech.* 2016 Aug;61(8):464-6.
- Sandulescu CM, Teow RY, Hale ME, Zhang C. Onset and dynamic expression of S100 proteins in the olfactory organ and the lateral line system in zebrafish development. *Brain Res.* 2011 Apr 6;1383:120-7.
- Schaffeld M, Herrmann H, Schultess J, Markl J. Vimentin and desmin of a cartilaginous fish, the shark *Scyliorhinus stellaris*: Sequence, expression patterns and in vitro assembly. *Eur J Cell Biol.* 2001 Nov;80(11):692-702.
- Schmitz RJ. Immunohistochemical identification of the cytoskeletal elements in the notochord cells of bony fishes. *J Morphol.* 1998 May;236(2):105-16.
- Yasumoto S, Koga D, Tanaka K, Kondo M, Takahashi Y. Histopathological and immunohistochemical studies of gonadal undifferentiated carcinoma in common carp *Cyprinus carpio*. *Fish Pathol.* 2015;50(2):53-9.

Received: December 21, 2019

Accepted: April 19, 2020

## **CHAPTER 4**

### **EXAMINATION OF WHITE BLOOD CELL PARAMETERS FOR THREE DIFFERENT PLOIDY LEVEL STURGEON SPECIES REARED IN AN INDOOR RECIRCULATION AQUACULTURE SYSTEM FOR ONE YEAR**

Salkova, E., Gela, D., Pecherkova, P., Flajshans, M., 2020. Examination of white blood cell parameters for three different ploidy level sturgeon species reared in an indoor recirculation aquaculture system for one year. Manuscript.

My share on this work was 70%.





**Examination of white blood cell parameters for three different ploidy level sturgeon species reared in an indoor recirculation aquaculture system for one year**

**Eva ŠÁLKOVÁ<sup>1</sup>, David GELA<sup>1</sup>, Pavla PECHERKOVÁ<sup>2</sup>, Martin FLAJŠHANS<sup>1</sup>**

<sup>1</sup>South Bohemian Research Center of Aquaculture and Biodiversity of Hydrocenoses, Faculty of Fisheries and Protection of Waters, University of South Bohemia in Ceske Budejovice, Ceske Budejovice, Czech Republic

<sup>2</sup> Department of Applied Mathematics, Faculty of Transportation Sciences, Czech Technical University in Prague, Czech Republic

corresponding author: Eva Šálková, pat.vesela.eva@email.cz, phone +420 728 182 830

**Abstract**

Juveniles of functionally diploid *Acipenser ruthenus*, functionally tetraploid *Acipenser gueldenstaedtii* and functionally hexaploid *Acipenser brevirostrum* were sampled monthly for one year, white blood cell parameters were determined. The total number of leukocytes (TL) was  $40.9317.24 \times 10^9/L$  for diploids,  $20.6311.20 \times 10^9/L$  for tetraploids,  $14.137.72 \times 10^9/L$  for hexaploids. TL decreased with increasing ploidy level. Highest number of leukocytes was reached during September and October for *A. ruthenus* and *A. brevirostrum*, from October to January for *A. gueldenstaedtii* (statistically significant finding). Lymphocytes dominated (76.89–80.14%) in differential counts and were found reduced in June and July in each group. Granulocytes were represented by neutrophils and eosinophils. Counting from all leukocytes, neutrophils represented 13.0–18.7% and eosinophils 5.7–6.1%, respectively. Increasing number of nuclear segments in granulocytes was dependent on increasing ploidy level. Nuclear segmentation in lymphocytes was common finding in higher ploidy level groups. Data suggest the significant effect of ploidy level on total number of leukocytes and morphological nuclear changes in granulocytes and lymphocytes. Annual variation in differential leukocyte counts depends on the species and influence of various external conditions rather than ploidy level.

**Key words:** *Acipenser brevirostrum*; *Acipenser gueldenstaedtii*; *Acipenser ruthenus*; differential leukocyte count; white blood cell count

**Acknowledgements**

The study was financially supported by the Ministry of Education, Youth and Sports of the Czech Republic: projects CENAKVA (LM2018099), Biodiversity (CZ.02.1.01/0.0/0.0/16\_025/0007370) and by the Czech Science Foundation (project No. 18-09323S).

The authors wish to acknowledge the technical assistance of M. Pečená and M. Kahanec from the South Bohemian Research Center of Aquaculture and Biodiversity of Hydrocenoses Faculty of Fisheries and Protection of Waters, University of South Bohemia in Ceske Budejovice. The authors wish to acknowledge the language help of dr. John F. Craig from Craig Consultancy, Whiteside, Dunscore, Dunfries, Scotland.

**Abbreviations:** RAS recirculation aquaculture system

## 1. Introduction

---

Sturgeons (Acipenseridae) are ancient fishes which are believed to be 'living fossils'. Their primitive ancestral characteristics and their ability to live in both freshwater and marine environments make them interesting to study their histology, physiology and genetics. Sturgeons have to face many infectious agents and they need a well-developed immune system to be able to survive. White blood cells represent an important component of immunological defence.

Haematological examination of fishes is a useful diagnostic tool for evaluation the physiological status and plays an important role in the diagnosis of different pathological conditions. Basic haematological parameters are represented by red blood cell indices, white blood cell indices (white blood cell count and differential white blood cell count), and platelets count (Knowles et al., 2006; Zexia et al., 2007; Docan et al., 2012; Svobodova et al., 2012).

While performing differential white blood cell count, lymphocytes, monocytes and granulocytes are recognized. The lymphocytes are round or spherical, with large basophilic nuclei and basophilic cytoplasm. The size of lymphocytes varies, small and large lymphocytes are recognized (Ellis, 1977; Knowles et al., 2006; Zexia et al., 2007). Granulocytes are classified as neutrophils, eosinophils and basophils according to their ultrastructural and histochemical grounds (Ellis, 1977; Ainsworth, 1992). Generally, in fish under physiological conditions, basophils seem to be rare cell subpopulation (Palikova et al., 1999; Zexia et al., 2007). Neutrophils vary in shapes, the nucleus is slightly basophilic, may occur as band or may be two- or several-segmented. The eosinophils have easily recognizable eosinophilic cytoplasmic granules. The nuclei are basophilic, may occur as bands or may be two- or several-segmented (Ainsworth, 1992; Svobodova et al., 2012). Monocytes are large cells with prominent eccentrically located horseshoe-shaped nucleus, slightly basophilic and vacuolated cytoplasm (Knowles et al., 2006; Zexia et al., 2007; Svobodova et al., 2012).

The study of sturgeon genetics can provide valuable data on mechanisms underlying the evolution of vertebrates. Sturgeons have evolved *via* allopolyploidization (Gregory and Witt, 2008; Smith and Gregory, 2009; Crow et al., 2012) by several polyploidization and hybridization events. Species of the genera *Acipenser*, *Huso*, *Scaphirhynchus* and *Pseudoscaphirhynchus* are separated into different classes according to chromosome numbers: (1) species with c. 120 chromosomes; (2) species with c. 250 chromosomes; (3) one species only, *Acipenser brevirostrum* Lesueur, 1818, having c. 360 chromosomes (Ludwig et al., 2001; Havelka et al., 2011, 2016). Havelka et al. (2011) stated that two scales of ploidy levels are recognized at present: the evolutionary scale, which presumes tetraploid (4n) – octaploid (8n) – dodecaploid (12n) relationships, referring to ancient ploidy levels, and the functional scale, which presumes diploid (2n) – tetraploid (4n) – hexaploid (6n) relationships arising from significant functional genome re-diploidization in sturgeon evolution.

Sturgeons exhibit large genomes among fishes (Gregory and Witt, 2008; Smith and Gregory, 2009). The increasing number of chromosomes is closely associated with the increase in DNA content in the cell nuclei. Cell and nuclear size correlate in a strongly positive mode with genome size and with each other at each taxonomic level, independently of phylogenetics and of ancient or neopolyploid status (Hardie and Hebert, 2003). Cytological features such as nuclear volume, cell volume, cell surface area and nuclear surface area also correlate in a positive manner with genome size (Palikova et al., 1999; Hardie and Hebert, 2003; Flajshans et al., 2011).

The aim of our study was sampling of different ploidy level representatives (sterlet *Acipenser ruthenus*, Russian sturgeon *Acipenser gueldenstaedtii* and shortnose sturgeon *A. brevirostrum*) over a year and evaluating white blood cell parameters in context of the ploidy level and season.

---

## 2. Material and methods

---

In this study, 10 specimens of juvenile functionally diploid (2n) *A. ruthenus* (initial age 8 months, total body length, TL 16 cm, body weight 31 g), 10 specimens of juvenile functionally tetraploid (4n) *A. gueldenstaedtii* (initial age of 6 months, TL 12 cm, body weight 24 g) and 10 specimens of juvenile functionally hexaploid (6n) *A. brevirostrum* (initial age of 2 months, TL 11 cm, body weight 6 g) were examined. Tested fish, representing specimens of particular ploidy level group, originated from the population of identical age and similar size representatives.

All fishes originated from the Genetic Fisheries Centre of the Faculty of Fisheries and Protection of Waters, University of South Bohemia in Ceske Budejovice, Czech Republic. The fishes were kept in an indoor recirculation aquaculture system (RAS) at a density of 10 kg.m<sup>-3</sup> in 3.2 m<sup>3</sup> tanks at 16–18 °C, with a feeding rate of 4% of the fish biomass daily using a commercial diet (Coppens® Supreme-10, Coppens International B.V., the Netherlands) containing 49% protein, 10% fat, 0.8% crude fibre and 7.9% ash.

Water temperature, dissolved oxygen, pH and water chemistry were monitored daily. Water temperature was maintained between 16–18 °C, but occasionally during the summer reached 20 °C. Generally, the temperature of inflowing water reached 16 °C. Dissolved oxygen in outflowing water ranged between 60–75%. Water pH was kept between 7 and 8. Concentration of nitrites was kept under 0.1 mg NO<sub>2</sub>-N. Daily water volume exchange in RAS was 10% of total water volume.

The tested fishes were visually healthy. Sampling was performed each month in a period of one year, starting in May and continuing until April. Sampling was performed during first half of the month, always within one day, thus interval between samplings was at least three weeks.

Blood samples were taken from the caudal blood vessel with a heparin-coated syringe and needle was adjusted for individual fish. According to our previous experience with rapid blood clotting, blood smears were taken immediately, dried at room temperature, fixed with methanol and stained using Hemacolor® Rapid staining set (Merck KGaG, Darmstadt, Germany). The slides obtained were inspected under an Olympus BHS microscope using x1,000 magnification. While performing leukocyte differential count, two hundred leukocytes were determined and counted for each specimen. Cellular size, nuclear morphology, cytoplasmic staining patterns were the criteria for cells identification and determination (Ellis, 1977; Ainsworth, 1992; Knowles et al., 2006; Zexia et al., 2007; Svobodova et al., 2012). Granulocytes were further classified as neutrophils and eosinophils, and in each subgroup the bands and segments were counted. The number of nuclear segments in neutrophils and eosinophils was also established for each ploidy level group. Differential leukocyte count was recorded as a percentage of particular cell type (Knowles et al., 2006; Svobodova et al., 2012). Only mature cells were involved in the leukogram, otherwise blasts and vanishing cells were excluded.

Blood samples for total number of leukocyte determination were stored in heparinized tubes and placed on ice until further analysis, but no longer than one hour. Heparinized blood was diluted 200 times with solution containing NaCl, Na<sub>2</sub>SO<sub>4</sub>, Na<sub>2</sub>HPO<sub>4</sub> · 12H<sub>2</sub>O, KH<sub>2</sub>PO<sub>4</sub>, formaldehyd and 1% cresyl violet diluted in distilled water (Svobodova et al., 2012). Total number of leukocytes was performed by counting white blood cells in a Bürker chamber and was recorded in 10<sup>9</sup>/L (Knowles et al., 2006; Svobodova et al., 2012). Thrombocytes and thrombocyte-like cells were not included in white blood cells parameters, since they represent distinct blood cell component (Khandekar et al., 2012).

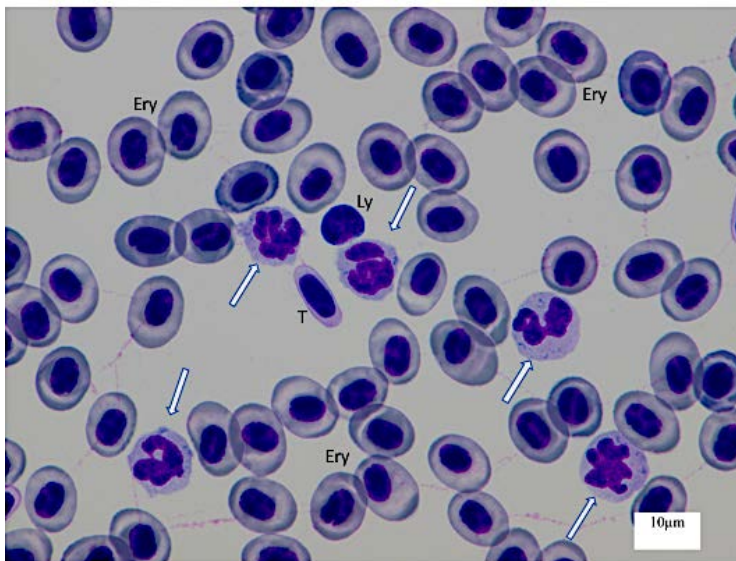
The study was carried out in accordance with the Czech Law No. 246/1992 'Animal welfare'. Protocols were supervised by the Institutional Animal Care and Use Committee (IACUC) of the University of South Bohemia (USB), Faculty of Fisheries and Protection of Waters (FFPW) in Vodňany. The USB FFPW has the approval of the Ministry of Agriculture of the Czech Republic for handling and usage of experimental animals (ref. no. 16OZ15759/2013-17214).

### 3. Statistical analysis

Analyses of haematological data were performed every month for one year. Mean was used as indicators of central tendency. For analysis of different blood components, the ANOVA test with Tukey's honestly significant difference test and t-test were used. Level of significance was 0.05. All P-values were interpreted descriptively, and no adjustment of P-values or significance levels was applied. Statistical analyses were performed using SPSS v23 (SPSS, Chicago, IL, USA) and Matlab R2018b software (The MathWorks, Inc., Natick, MA, USA)

### 4. Results

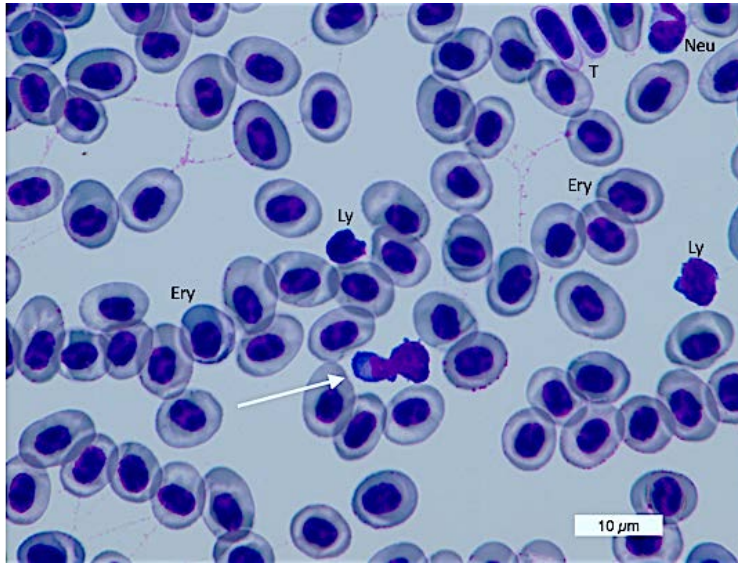
Nuclear changes of granulocytes (multinucleated nuclei, atypical nuclear shapes and increasing number of nuclear segments) were common in higher ploidy level groups (see Figure 1) (statistical significant finding). Changes were related to increasing genome size and DNA folding. Increasing ploidy level in lymphocytes was associated with the tendency for nuclei to divide, and the nucleus revealed 'budding' appearance (see Figure 2).



**Figure 1.** Blood smear, *Acipenser brevirostrum* (6n), Hemacolor® Rapid staining set, (magnification 1000x, scale bar 10 μm).

Erythrocytes (Ery) dominate in blood smear. Thrombocytes (T) are spindle or fusiform, with elongated nucleus. Lymphocytes (Ly) are round or spherical, with large basophilic nuclei and thin rim of basophilic cytoplasm. Nuclear changes of granulocytes including atypical nuclear shapes and increasing number of nuclear segments (indicated by arrows) are common findings in higher ploidy level groups.

*Examination of white blood cell parameters for three different ploidy level sturgeon species reared in an indoor recirculation aquaculture system for one year*



**Figure 2.** Blood smear, *Acipenser brevirostrum* (6n), Hemacolor® Rapid staining set (magnification 1000x, scale bar 10 μm).

Lymphocytes (Ly) are round or spherical, with basophilic nuclei and thin rim of basophilic cytoplasm. Increasing ploidy level in lymphocytes is associated with the tendency to nuclei division. Arrow points to the 'budding' appearance of nucleus in lymphocyte. Neutrophils (Neu) represent granulocytic group, different developmental stages are present (bands or segments). Erythrocytes (Ery) dominate in blood smear. Thrombocytes (T) are oval, spindle or fusiform and occur as single cells or may constitute clusters or small groups.

### 4.1. Total number of leukocytes

The total number of leukocytes over the year ranged between  $40.93 \pm 17.24 \times 10^9/L$  for *A. ruthenus*,  $20.63 \pm 11.20 \times 10^9/L$  for *A. gueldenstaedtii* and  $14.13 \pm 7.72 \times 10^9/L$  for *A. brevisrostrum* (summary in Table 1). Statistically significant differences ( $P < 0.001$ ) in the total number of leukocytes were found for each group within the year, with highest number of leukocytes reached during autumn (September and October) for *A. ruthenus* ( $45.5 \times 10^9/L$  and  $63.0 \times 10^9/L$ ) and for *A. brevisrostrum* ( $22.0 \times 10^9/L$  and  $20.5 \times 10^9/L$ ) and during autumn and winter (October until January) for *A. gueldenstaedtii* (from  $21.0 \times 10^9/L$  to  $27.0 \times 10^9/L$ ). The lowest value was reached in November for *A. ruthenus* ( $28.0 \times 10^9/L$ ), in July for *A. gueldenstaedtii* ( $13.0 \times 10^9/L$ ), and in February for *A. brevisrostrum* ( $7.5 \times 10^9/L$ ). Annual variation in the total number of leukocytes is given in Graph 1.

**Table 1.** Summary of white blood cells (WBC) parameters within different ploidy level groups (*Acipenserid* species).

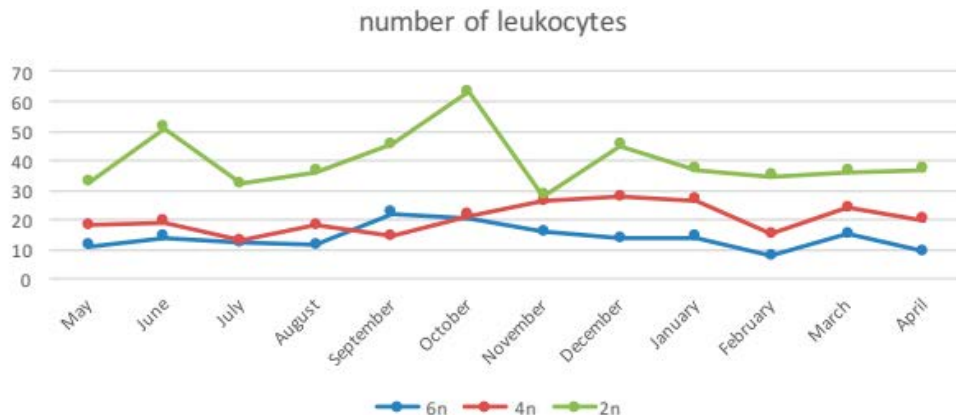
Total number of leukocytes ( $10^9/L$ ), differential leukocyte counts comprising lymphocytes, monocytes and granulocytes counts recorded as percentages. Granulocytic content within total number of leukocytes and proportion of developmental stages recorded as bands and segments are presented. Values are recorded as mean *SD*. Data with \* show statistically significant difference at  $P = 0.001$ , data with \*\* point at statistically significant difference at  $P < 0.0001$ , NS = not specific.

	Ploidy level, functional scale	WBC ( $\times 10^9/L$ )	Lymphocytes (%)	Monocytes (%)	Granulocytes (%)	Granulocytes bands (%)	Granulocytes segments (%)
<i>A. ruthenus</i>	2n	$40.9 \pm 17.2$ ***	$77.6 \pm 8.5$ *	$0.9 \pm 0.7$ NS	$21.6 \pm 8.2$ *	$15.6 \pm 5.3$ *	$5.8 \pm 1.8$ NS *
<i>A. gueldenstaedtii</i>	4n	$20.6 \pm 11.2$ **	$80.1 \pm 8.1$ *	$1.0 \pm 0.8$ NS	$18.0 \pm 7.8$ *	$10.1 \pm 3.4$ NS	$7.4 \pm 2.6$ *
<i>A. brevisrostrum</i>	6n	$14.1 \pm 7.7$ **	$76.9 \pm 7.8$ *	$1.1 \pm 0.9$ NS	$22.0 \pm 7.5$ *	$10.1 \pm 3.1$ NS	$10.5 \pm 4.3$ *

NS not specific

\*  $p < 0.01$

\*\*  $p < 0.0001$

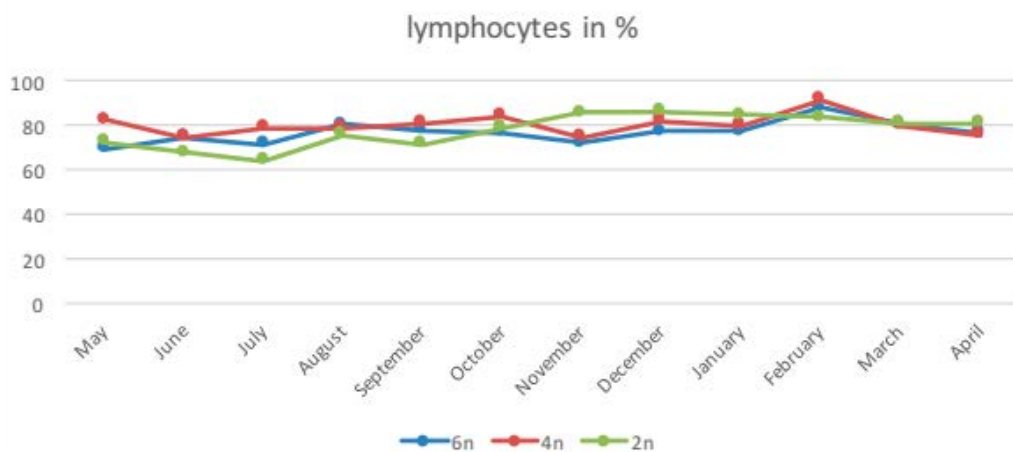


**Graph 1.** Total number of leukocytes.

The annual variation in total number of leukocyte (TL) within different ploidy level groups is presented. Axis x represents time schedule as months in year, study has been running since May till April. Axis y marks mean of TL recorded in  $10^9/L$ . Increasing ploidy level is associated with decreasing TL. Seasonal changes are evident: Highest number of leukocytes was reached during September and October for *A. ruthenus* (2n) and *A. brevisrostrum* (6n), from October to January for *A. gueldenstaedtii* (4n). Seasonal changes in TL within each ploidy level group are statistically significant.

## 4.2. Lymphocytes

Lymphocytes dominated in differential leukocyte counts regardless of species or ploidy level. Lymphocytes constituted 77.598.45% in *A. ruthenus*, 80.148.13% in *A. gueldenstaedtii* and 76.897.82% in *A. brevirostrum*. Statistically significant differences were found between *A. gueldenstaedtii* and *A. ruthenus*, and between *A. gueldenstaedtii* and *A. brevirostrum* (Table 1). Reduced numbers of lymphocytes were documented in June and July for each ploidy group (statistically significant). Annual variation in lymphocyte differential counts is given in Graph 2.



**Graph 2.** The annual variation of lymphocytes.

Axis x represents study time schedule as months in year, study has been running since May till April. Axis y marks mean lymphocyte count recorded as %. Lymphocytes dominated (76.89–80.14%) in differential counts and were found reduced in June and July in each ploidy level group (statistically significant).

## 4.3. Granulocytes

Three types of granulocytes were determined in the sturgeons, i.e. neutrophils, eosinophils and basophils. No basophils were recognized in any specimens. From all leukocytes, granulocytes represented 21.638.2% in *A. ruthenus*, 18.857.75% in *A. gueldenstaedtii* and 22.047.47% in *A. brevirostrum* (Table 1). Statistically significant differences were found between *A. brevirostrum* (6n) and *A. gueldenstaedtii* (4n), and between *A. brevirostrum* (6n) and *A. ruthenus* (2n) (Table 1). In contrast to lymphocytes, the highest number of granulocytes was reached during April and June in *A. gueldenstaedtii* and during June and July in *A. ruthenus* and *A. brevirostrum*. Evaluating blood smears, different developmental stages of granulocytes were evident, granulocytic bands and segments were present: bands constituted 10.1–15.6 % and segments comprised 5.8–10.5 % (Table 1).

Regarding particular granulocytes, neutrophils dominated and constituted 70.0–75.0% of granulocytes, and 13.1–18.7% of all leukocytes, respectively. Eosinophils represented 25.0–32.0% of granulocytes and 5.6–6.0% of all leukocytes. Ploidy level did not influence percentage of neutrophils and eosinophils in granulocytic subgroup.

Increasing number of nuclear segments in granulocytes was evident and dependent on the increasing ploidy level status. Statistically significant differences were found between

*A. breviostrum* (6n) and *A. gueldenstaedtii* (4n) as well as between *A. breviostrum* (6n) and *A. ruthenus* (2n). White blood cells parameters are summarized in Table 1. Granulocytic parameters are presented in Table 2.

**Table 2.** Granulocytic parameters within different ploidy level groups in details.

Granulocytes are classified as neutrophils and eosinophils, number of nuclear segments in each granulocytic subgroup is recorded. Values are recorded as mean SD. Data with \* show statistically significant difference at  $P < 0.01$ , data with \*\* point at statistically significant difference at  $P < 0.0001$ . NS = not specific.

	Ploidy level, functional scale	Neutrophils(%)	Neutrophils: number of nuclear segments	Eosinophils(%)	Eosinophils: number of nuclear segments
<i>A. ruthenus</i>	2n	18.7±9NS	2.6	5.8±3.2NS	2.05
<i>A. gueldenstaedtii</i>	4n	13.1±7NS	3.1	5.6±2.8NS	2.6
<i>A. breviostrum</i>	6n	15.5±9NS	4.1	6±4.9NS	3.3

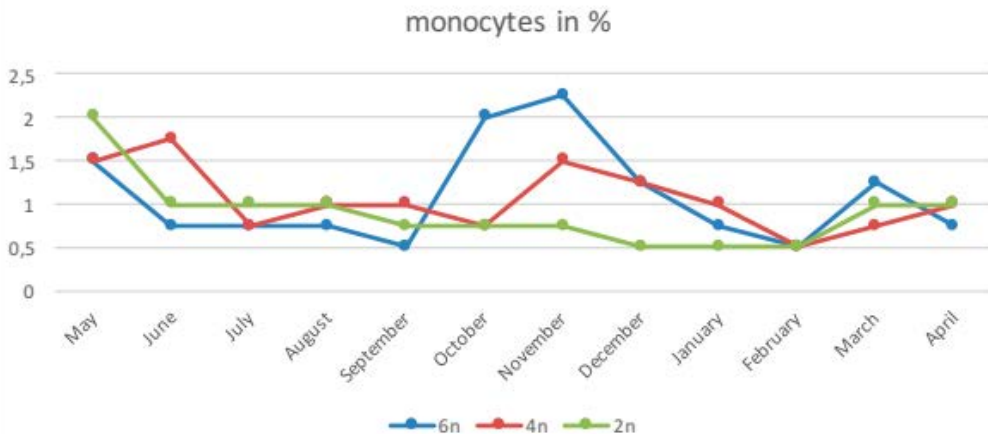
\*  $p = 0.001$

\*\*  $p < 0.001$

NS not specific

#### 4.4. Monocytes

Monocytes were easily recognized in blood smears due to their size, nuclear shape and cytoplasmic tincture. From all leukocytes, monocytes represented 0.850.66% in *A. ruthenus*, 1.000.81% in *A. gueldenstaedtii* and 1.060.94% in *A. breviostrum*. No statistically significant differences were found between ploidy level groups. The highest number of monocytes was reached in May for *A. ruthenus*, in June for *A. gueldenstaedtii* and in November for *A. breviostrum*. Annual variation in monocyte differential counts is given in Graph 3.



**Graph 3.** The annual variation of monocytes.

Axis x represents study time schedule as months in year, study has been running since May till April. Axis y marks mean monocyte count recorded as %. The highest number of monocytes was reached in May for *A. ruthenus*, in June for *A. gueldenstaedtii* and in November for *A. breviostrum*.



---

## 5. Discussion

---

### 5.1. Polyploidy in sturgeons and number of leukocytes

---

Sturgeons are well known for their polyploidy (Flajshans and Vajcova, 2000; Ludwig et al., 2001; Havelka et al., 2011, 2016; Crow et al., 2012). It is now believed, that polyploidization might represent an important phenomenon in the evolution of fishes (Hardie and Hebert, 2003; Havelka et al., 2011). Cell and nuclear size both correlate strongly with genome size and with each other in ray-finned and cartilaginous fishes. These relationships remain significant at each taxonomic level and exist independently of phylogeny (Hardie and Hebert, 2003). The chromosome number positively correlates with DNA content among fishes (Smith and Gregory, 2009). Increased cellular and nuclear volume due to the additional chromosomal set or sets is balanced by reduced cell numbers (Benfey, 1999; Maxime, 2008). The same observations were made in studies documenting changes in physiology and, especially, haematology of sturgeons with different ploidy levels (*Acipenser baerii*, *Acipenser stellatus*, *Huso huso* in Palikova et al., 1999; *A. ruthenus*, *A. gueldenstaedtii*, *A. baerii* in Flajshans and Vajcova, 2002; *A. persicus* Borodin, 1897, *H. huso* in Bahmani et al., 2001; *A. baerii* in Havelka et al., 2016). Similar results were obtained from studies comparing haematological profiles between diploids and induced triploids (*A. brevirostrum* in Beyea et al., 2005; *A. baerii* in Wlasow and Fopp-Bayat, 2011; *A. baerii* in Fopp-Bayat et al., 2013; *A. baerii* in Rozynski et al., 2015).

Our results showed a dependence between the total number of leukocytes and the ploidy level. Statistically significant was the increasing ploidy level associated with the decreasing total number of leukocytes. Our results were thus in agreement with other studies, especially with Hardie and Hebert (2003). The total number of leukocytes revealed ploidy specificity and dependence.

### 5.2. Annual and seasonal changes in blood cells parameters, general considerations

---

Available haematological data of annual and seasonal changes in blood cells parameters are scarce, especially for sturgeons, and have concentrated mostly on red blood cells. Haematological data on white blood cell parameters were collected from specimens reared in indoor recirculation aquaculture systems (*H. huso* in Zarejabad et al., 2009a,b; Akrami et al., 2013; *A. baerii* in Fopp-Bayat et al., 2013 and Rozynski et al., 2015; *A. ruthenus*, *A. baerii*, *A. gueldenstaedtii* in Flajshans and Vajcova, 2002; *A. brevirostrum* in Knowles et al., 2006), or obtained from wild caught fishes (*A. stellatus* in Docan et al., 2014; *H. huso* in Mazandarani et al., 2015; *A. persicus*, *A. stellatus* in Pourgholam and Saeidi, 2000; *A. brevirostrum* in Matsche and Gibbons, 2012 and Matsche et al., 2013). Sturgeons investigated were of different age (juveniles, adults or unknown age of wild caught fishes), gender, ploidy level, number of samples, and from different environmental conditions. Continuous blood analysis of red or white blood cell parameters have rarely exceeded 3 months. Data for selected periods of the year (spring, autumn) were documented for *A. stellatus* (Docan et al., 2014), *A. brevirostrum* (Matsche and Gibbons, 2012; Matsche et al., 2013) and *A. persicus* (Pourgholam et al., 2000).

### 5.3. Lymphocytes

---

Generally, differential white blood cell counts in sturgeons were of lymphocytic origin in each of the abovementioned studies. Exceptionally, thrombocytes and thrombocytes-like cells were encountered in two differential counts (Knowles et al., 2006; Zexia et al., 2007). Nowadays, thrombocytes are believed to belong to an individual blood cell category (Khandekar et al.,

2012) with unique function and origin. Lymphocytes constituted 70–80% from all leukocytes, rarely only 51% (Matsche and Gibbons, 2012; Palanisamy et al., 2016), or reached up to 98% (Rozynski et al., 2015) from all leukocytes. Marginal values might be achieved owing to special or specific experimental or environmental conditions. In our study, lymphocytes ranged between 76.89–80.14%, and thus, the results were in accordance with other studies. Increasing ploidy level in lymphocytes was associated with the tendency to nuclei division, the nucleus revealed a 'budding' appearance. In our study, 'budding' appearance in lymphocytes was first made in the tetraploids (*A. gueldenstaedtii*). This finding seemed to be analogous to erythrocyte nuclei divisions reported by Beyea et al. (2005) in triploid *A. brevirostrum* and Wlasow and Fopp-Bayat (2011) in triploid *A. baerii*. Our observation of lymphocyte nuclear division, however, was in contrast with findings made by Wlasow and Fopp-Bayat (2011) in lymphocytes.

#### 5.4. Granulocytes

---

When studying granulocytes, some scientists have determined neutrophils, eosinophils and basophils (Pourgholam et al., 2000; Flajshans and Vajcova, 2002; Ruchin, 2007; Zexia et al., 2007; Zarejabad et al., 2009a,b; Docan et al., 2012; Matsche and Gibbons, 2012; Akrami et al., 2013; Mazandarani et al., 2015; Palanisamy et al., 2016), others have provided additional classification of different developmental stages (Palikova et al., 1999; Fopp-Bayat et al., 2013), or focused on counting number of nuclear segments (Fopp-Bayat et al., 2013; Rozynski et al., 2015; Wlasow and Fopp-Bayat, 2011). Generally, neutrophils dominated, eosinophils occurred in each study, always with less frequency compared to neutrophils. Gharaei et al. (2016) reported only basophils as granulocytic representatives in *H. huso*. In our study, neutrophils dominated in each ploidy level group, and constituted 13.1–18.7% from all leukocytes. Eosinophils constituted 5.6–6.0% from all leukocytes. Our results on granulocytes were in accordance with other studies. Statistically significant was the dependence between the increasing number of nuclear segments both in neutrophils and eosinophils and increasing ploidy level. Similar findings were documented by Wlasow and Fopp-Bayat (2011) in *A. baerii*.

#### 5.5. Monocytes

---

Reports about monocytes in differential counts were often conflicting; some authors did not mention monocytes in differential counts at all (Wlasow and Fopp-Bayat, 2011; Fopp-Bayat et al., 2013), other authors pointed out monocytes sporadic occurrence (Palikova et al., 1999). Based on our results, monocytes constituted 0.85–1.06% from all leukocytes, and were in accordance with published results.

#### 5.6. Ploidy level representatives' assessment and comparison

---

##### 5.6.1. Diploid group

---

Of interest were the results of white blood cell parameters measured between representatives of particular ploidy level groups. Comparison of species was done upon the functional ploidy level scale (Havelka et al., 2011). White blood cells parameters found for *A. ruthenus* under study were compared to published data for sturgeons of same ploidy level, i.e. *A. ruthenus*, *H. huso* and *A. stellatus* (summary in Table 3). Palikova et al. (1999) evaluated white blood cell profile of *A. stellatus* with corresponding results as for *A. ruthenus* in our study. Pourgholam and Saeidi (2000) performed evaluations from wild adults of *A. stellatus* with a lower total leukocytes and lymphocytes compared to our data, and with increased number of granulocytes.

Flajshans and Vajcova (2000) reported a lower total leukocyte in *A. ruthenus* compared to our results, as well as slightly decreased eosinophils and slightly elevated monocytes. Bahmani et al. (2001), Bani et al. (2009), Akrami et al. (2013) and Mazandarani et al. (2015) presented a corresponding total leukocyte for *H. huso* as a diploid representative compared to our data from *A. ruthenus*. In contrast, Gharaei et al. (2016) and Zarejabad et al. (2009a,b) reported a significantly lower total leukocyte in *H. huso*. Lymphocytes dominated and reached 54–75%.

The majority of sturgeons examined originated from the hatchery and juveniles dominated in the studies. Pourgholam and Saeidi (2000) examined wild adults of *A. stellatus*, and Akrami et al. (2013) performed haematological examination of *H. huso* of different ages reared in ponds.

**Table 3.** White blood cells parameters measured between representatives of diploid group.

		Ploidy level 2n											
<i>Acipenser ruthenus</i>		<i>Huso huso</i>										<i>Acipenser stellatus</i>	
	Our study	Flajshans and Vajcova (2002)	Akrami et al. (2013)	Palikova et al. (1999)	Bani et al. (2009)	Shahsavani et al. (2004)	Mazandarani et al. (2015)	Bahmani et al. (2001)	Zarejabad et al. (2009)	Gharaei et al. (2016)*	Zarejabad et al. (2019)	Palikova et al. (1999)	Pourgholam and Saeidi (2000)
WBC 10 <sup>9</sup> /l	40.93±17.24	10.6±4.6	23–25	NA	37–52	4	23 ♀ 24.9 ♂	31–57.7	18–22	6.8	18	NA	16.5±4
Lym %	77.59±8.45	76.6±9	68–72	73	NA	75	68.4 ♀ 72.4 ♂	54.5–67.5	56–69	74	58	73	52
Neu %	18.7±9	17.2±8.5	18–20.5	22	NA	20.56	21.4 ♀ 18.6 ♂	22–33	24–56	no	28	21	36
Eos %	5.8±2.8	1.2±1.8	5.5–6.5	5	NA	2.2	7 ♀ 4.6 ♂	6.6–13.7	6–14	no	13	4	11.9
Mono %	0.85±0.66	2.6±2.2	3.3–4.2	NA	NA	0.342	3.2 ♀ 4 ♂	0.6–2.25	0.3–0.6	4	1	NA	0.1

### 5.6.2. Tetraploid group

Published data on white blood cell parameters in *A. baerii*, *A. persicus* and *A. sinensis* were used for comparative purposes in the tetraploid group (summary in Table 4). Comparing results from *A. gueldenstaedtii* in our study, the corresponding total leukocyte and differential counts were reported by Flajshans and Vajcova (2000), Docan et al. (2012) and Rozynski et al. (2015) in *A. baerii*. In contrast, Ruchin (2007) documented a higher total leukocyte in *A. baerii*. Changes in lymphocyte percentages in *A. baerii* decreased in studies provided by Palikova et al. (1999), Wlasow and Fopp-Bayat (2011), Fopp-Bayat et al. (2013). Increased lymphocytes were documented in the study of Ruchin (2007). Bahmani et al. (2001) provided evaluation in *A. persicus* with corresponding results, Pourgholam and Saeidi (2000) and Palanisamy et al. (2016) documented a decreased total of leukocytes compared to our results. Decreased lymphocytes were most prominent in the study of Palanisamy et al. (2016) and reached up to 51%. The most confusing results were found in the study of Zexia et al. (2007) on *A. sinensis*; platelets were encountered in the white blood cell count, and monocytes represented the majority in the differential leukocyte count followed by lymphocytes and neutrophils. The majority of sturgeons studied originated from hatcheries and juveniles dominated. Palanisamy et al. (2016) presented a comparison of haematological indices between *A. persicus* adult males and females.

**Table 4.** White blood cells parameters measured between representatives of tetraploid group.

Ploidy level 4n													
<i>Acipenser gueldenstaedtii</i>		<i>Acipenser baerii</i>							<i>Acipenser persicus</i>				<i>Acipenser sinensis</i>
	Our study	Docan et al. (2012)	Fopp-Bayat et al. (2013)	Wlasow and Fopp-Bayat (2011)	Palliková et al. (1999)	Flajshans and Vajcova (2002)	Ruchin (2007)	Rozynski et al. (2015)	Pourgholam and Saeidi (2000)	Bahmani et al. (2001)	Palanisaamy et al. (2016)	Padash et al. (2010)	Zexia et al. (2007)**
WBC 10 <sup>9</sup> /l	20.63±11.20	20	NA	NA	NA	20.1±11	30–43.7	NA	10±4	13–46	10–14	1.25	22.4
Lym %	80.14±8.13	70–77	60	69	68	74±15	83–90	86 (69–98)	70	73–82	44.5–51	82.6	12
Neu %	13.1±7	15–25	35*	28*	25	12.9±9	3–7	14.5*	22	12–20	45–50	15*	11
Eos %	5.6±2.8	2.9–4	0.6	2.2	3	8.8±8.3	0.5–1	2.5	7	2–6.5	0.23–0.69	2*	4
Mono %	1.00±0.81	1–2	NA	NA	NA	1.8±1.6		5	1	0.2–2.5	0.7–1.1	0	13

\*Authors presented developmental stages of neutrophils or eosinophils, respectively; number represents total count of different neutrophilic/eosinophilic subtypes.

\*\*Zexia et al. (2007) included thrombocytes into white blood cell differential count, thrombocytes consisted 60% of white blood cells.

NA data not available.

### 5.6.3. Hexaploid group

Haematological data on white blood cell parameters from *A. brevirostrum* are rare. Comparing our results, summarized in Table 5, corresponding data for total number of leukocytes were documented by Matsche and Gibbons (2012) and Matsche et al. (2013), while Knowles et al. (2006) presented a significantly higher total leukocyte. Neutrophils dominated in the study of Matsche and Gibbons (2012) in most examined fish owing to long lasting stress. Knowles et al. (2006) encountered thrombocytes-like cells in differential counts, but despite this, lymphocytes dominated in the differential count. Results obtained from Matsche and Gibbons (2012) and Matsche et al. (2013) reflected the haematological profiles of adult fish during spawning activity, while data obtained from Knowles et al. (2006) were based on immature cultured fish.

**Table 5.** White blood cells parameters measured between representatives of hexaploid group.

Ploidy level 6n			
<i>Acipenser brevirostrum</i>			
	Our study	Knowles et al. (2006)*	Matsche et al. (2012, 2013)*
WBC 10 <sup>9</sup> /l	14.13±7.72	57 (28–90)	2.08–8.74
Lym %	76.89±7.82	39–74**	30
Neu %	15.5±9	13–37	51
Eos %	6±4.1	0–1.7	2
Mono %	1.06±0.94	0–7.8	3

\*Authors presented differential leukocyte count as number of particular cell type and reference interval.

\*\*Lymphocytes were originally subdivided as small and large lymphocytes, the number represents the total count of lymphocytes.

## 5.7. Conclusion

---

Results obtained from a variety of studies documented changes in haematological and biochemical parameters under different influences and conditions, and thus represented useful knowledge about sturgeon physiology and their ability to adapt. Results have often been provided for comparative purposes and have been reported as descriptive summaries.

To our current knowledge, there has not been any standardised guidelines published for sampling sturgeon blood parameters. This is not surprising since fishes have revealed high variability in blood cell parameters among species and under different environmental and anthropogenic conditions.

The periodical and annual examination of fish populations as described in our study appear to be unique. The data obtained contributed to basic knowledge on sturgeon physiology, especially haematology. The total number of leukocytes was dependent on the ploidy level, while the variations in differential counts during annual examination were species specific. Thus, knowledge of seasonal changes in white blood cell parameters should be taken into account while performing haematological examinations.

The authors declare no conflict of interest.

## 6. References

---

- Ainsworth, A.J., 1992. Fish granulocytes: morphology, distribution and function. Annual. Rev. of Fish Diseases 123–148.
- Akrami, R., Gharaei, A., Karami, R., 2013. Age and sex specific variation in haematological and serum biochemical parameters of Beluga (*Huso huso* Linnaeus, 1758). International Journal of Aquatic Biology 1, 132–137.
- Bahmani, M., Kazemi, R., Donskaya, P., 2001. A comparative study of some haematological features in young reared sturgeons (*Acipenser persicus* and *Huso huso*). Fish Physiol. Biochem. 24, 135–140.
- Bani, A., Tabarsa, M., Falahatkar, B., Banan, A, 2009. Effects of different photoperiods on growth, stress and haematological parameters in juvenile great sturgeon *Huso huso*. Aquac. Res. 40, 1899–1907.
- Benfey, T.J., 1999. The physiology and behaviour of triploid fishes. Rev. Fish. Sci. 7,36–67.
- Beyea, M.M., Benfey, T.J., Kieffer, J.D., 2005. Hematology and stress physiology of juvenile diploid and triploid shortnose sturgeon (*Acipenser brevirostrum*). Fish Physiol. Biochem. 31, 303–313.
- Crow KC, Smith CD, Cheng JF, Wagner GP, Amemiya CA. An independent genome duplication inferred from Hox paralogs in the American paddlefish– a representative basal ray-finned fish and important comparative reference. Genome Biol Evol. 2012 (4 ):937–53.
- Docan, A., Dediu, L., Cristea, V., 2012. Effect of feeding with different dietary protein level on leukocytes population in juvenile Siberian sturgeon, *Acipenser baerii* Brandt. Archiva Zootechnica 15, 59–67.
- Docan, A., Dediu, L., Grecu, I., Cristea, V., Maoreanu, M., 2014. Hematological profiles of mature *Acipenser stellatus* from Danube river during spring season. Lucrart Stiintifice – Seria Zootehnie 62, 143–146

- Ellis, A.E., 1977. A leukocyte of fish: A review. doi.org/10.1111/j.1095-8649.1977.tb04140.x
- Flajshans, M., Vajcova, V., 2000. Odd ploidy levels in sturgeon suggest a backcross of interspecific hybrids to evolutionary tetraploid and/or octaploid parental species. *Folia Zool.* 49, 133–138.
- Flajshans, M., Vajcova, V., 2002. Differences in haematological indices of sturgeons with different ploidy levels. *Biodiverzita Ichtýofauny ČR IV*, pp. 59–64.
- Flajshans, M., Psenicka, M., Rodina, M., Tesitel, J., 2011. Image cytometric measurements of diploid, triploid and tetraploid fish erythrocytes in blood smears reflect the true dimensions of live cells. *Cell Biol. Int.* 35, 67–71.
- Fopp-Bayat, D., Wlasow, T., Ziomek, E., 2013. Haematology of gynogenetic diploids of Siberian sturgeon *Acipenser baerii* Brandt. *Acta Vet. BRNO* 82, 81–85.
- Gharaei, A., Rayeni, M.F., Ghaffari, M., Akrami, R., Ahmadifar, E., 2016. Influence of dietary probiotic mixture ( $\alpha$ -mune) on growth performance, haematology and innate immunity of Beluga sturgeon (*Huso huso*) juvenile. *International Journal of Aquatic Biology* 4, 277–284.
- Gregory, T.R., Witt, J.D.S., 2008. Population size and genome size in fishes: a closer look. *Genome* 51, 309–313.
- Hardie, D.C., Hebert, P.D.N., 2003. The nucleotypic effects of cellular DNA content in cartilaginous and ray-finned fishes. *Genome* 46, 683–706.
- Havelka, M., Kaspar, V., Hulak, M., Flajshans, M., 2011. Sturgeon genetics and cytogenetics: a review related to ploidy levels and interspecific hybridization. *Folia Zool.* 60, 93–103.
- Havelka, M., Bytyutskyv, D., Symonova, R., Rab, P., Flajshans, M., 2016. The second highest chromosome count among vertebrates is observed in cultured sturgeon and is associated with genome plasticity. *Genet Sel Evol.* 48,1–9.
- Khandekar, G., Kim, S., Jagadeeswaran, P., 2012. Zebrafish thrombocytes: Functions and Origins. *Adv. Hematol.* 2012, 857058.
- Knowles, S., Hrubec, T.C., Smith, S.A., Bakal, R.S., 2006. Hematology and plasma chemistry reference intervals for cultured shortnose sturgeon (*Acipenser brevirostrum*). *Vet. Clin. Pathol.* 35, 434–440.
- Ludwig, A., Belfiore, N.M., Pitra, C., Svirsky, V., Jenneckens, I., 2001. Genome duplication events and functional reduction of ploidy levels in sturgeon (*Acipenser*, *Huso* and *Scaphirhynchus*). *Genetics* 158, 1203–1215.
- Matsche, M.A., Gibbons, J., 2012. Annual variation of hematology and plasma chemistry in shortnose sturgeon, *Acipenser brevirostrum*, during a dam-impeded spawning run. *Fish Physiol. Biochem.* 38, 1679–1696.
- Matsche, M.A., Rosemary, K.M., Brundage, III H.M., O'Herron, II J.C., 2013. Hematology and plasma chemistry of wild shortnose sturgeon *Acipenser brevirostrum* from Delaware River, USA. *J. Appl. Ichthyol.* 29, 6–14.
- Maxime, V., 2008. The physiology of triploid fish: current knowledge and comparison with diploid fish. *Fish. Fish.* 9, 67–78.
- Mazandarani, M., Taheri, Mirghaed, A., Hoseini, S.M., 2015. Hematological characteristics and reproduction indices of wild beluga (*Huso huso*) broodstocks from the southeast of the Caspian Sea. *Iranian Journal of Veterinary Medicine* 9, 65–71.

- Palanisamy, S.K., Shafiei, S., Fazli, H., Zorriehzahra, J., 2016. Comparative study of haematological, serum electrolyte and nonelectrolyte parameters of male and female Persian sturgeon (*Acipenser persicus*) brood stocks. *Acta Oceanol. Sin.* doi: 10.1007/s13131-016-0869-y.
- Palikova, M., Mares, J., Jirasek, J., 1999. Characteristics of leukocytes and thrombocytes of selected sturgeon species from intensive breeding. *Acta Vet. BRNO* 68, 259–264.
- Pourgholam, R., Saeidi, A.A., 2000. Evaluation of some haematological variables of *Acipenser persicus* and *Acipenser stellatus* at different water temperature. *Iran. J. Fish. Sci.* 2, 53–58.
- Rozynski, M., Demska-Zakes, K., Fopp-Bayat, D., 2015. Hematological and blood gas profiles of triploid Siberian sturgeon (*Acipenser baerii* Brandt). *Arch. Pol. Fish.* 25, 197–203.
- Ruchin, A.B., 2007. Effect of photoperiod on growth, physiological and haematological indices of juvenile Siberian sturgeon *Acipenser baerii*. *Biol. Bull* 34, 583–589.
- Smith, E.M., Gregory, T., 2009. Patterns of genome size diversity in the ray-finned fishes. *Hydrobiologia* 625, 1–25.
- Svobodova, Z., Pravda, D., Modra, H., 2012. Unified methods of fish haematological investigations. RIFCH Vodnany, Edition of Methods, No. 122. 29 pp. (in Czech)
- Wlasow, T., Fopp-Bayat, D., 2011. The effect of thermal shock on morphological characteristics of blood cells in Siberian sturgeon (*Acipenser baerii*) triploids. *Acta Vet. BRNO* 80, 215–218.
- Zarejabad, A.M., Jalali, M.A., Sudagar, M., Bastami, K.D., 2009a. Haematology of great sturgeon (*Huso huso* Linnaeus, 1758) juvenile exposed to brakish water environment. *Comp. Clin. Pathol.* 1, DOI 10.1007/s00580-009-0888-6.
- Zarejabad, A.M., Sudagar, M., Poralimotlagh, S., Bastami, K.D., 2009b. Effects of rearing temperature on haematological and biochemical parameters of great sturgeon (*Huso huso* Linnaeus, 1758) juvenile. *Comp. Clin. Pathol.* 19, 367–371. DOI 10.1007/s00580-009-0880-1.
- Zexia, G., Weimin, W., Yi, Y., Abbas, K., Dapeng, L., Guiwei, Z., Diana, J.S., 2007. Morphological studies of peripheral blood cells of the Chinese sturgeon, *Acipenser sinensis*. *Fish Physiol. Biochem.* 33, 213–222.





## **CHAPTER 5**

**GENERAL DISCUSSION**

**ENGLISH SUMMARY**

**CZECH SUMMARY**

**ACKNOWLEDGEMENTS**

**LIST OF PUBLICATIONS**

**TRAINING AND SUPERVISION PLAN DURING THE STUDY**

***CURRICULUM VITAE***



## General discussion

Sturgeons have lived on Earth for a long period of time. Acipenseriform fishes first appeared in fossil records of approximately 200 million years, already during the Jurassic period (Peng et al., 2007). Their well-developed immune system has enabled sturgeons to face and deal with different attacks (e.g., infections, stress, external environmental conditions). There is a variety of organs and tissues involved in sturgeon haematopoiesis and lymphopoiesis, respectively (Scharrer, 1944; Mattisson and Fänge, 1982; Tavassoli, 1986; Fänge, 1986; Manca et al., 2019). However, none of these possess the structure and organization known from the marrow of higher vertebrates. The interstitial tissue in the anterior portion of the kidney represents the main erythropoietic tissue in sturgeons. Moreover, the spleen is also involved in erythropoiesis. It is remarkable that sturgeons developed unique haematopoietic tissues not seen in higher vertebrates. Meningeal myeloid and pericardial myeloid tissues represent sites, where granulopoiesis, thrombopoiesis, erythropoiesis and less frequently lymphopoiesis take place (Scharrer, 1944; Fänge, 1986). The main lymphoid organ is the thymus (Fänge, 1986; Salkova and Flajshans, 2016). Lymphoid masses, usually found in the intestinal mucosa or less frequently in skin, gills and oral cavity also represent an important tissue for sturgeon protection. Examination of white blood cell parameters and their evaluation reflect fish physiological status and play an important role in the diagnosis of different pathological conditions. Haematological examination thus represents relatively cheap, easily accessible testing, which provides valuable data concerning fish health status.

### Histology of lymphoid organs

In our first study, we focused on the morphological mapping of the thymic microenvironment (Salkova and Flajshans, 2016). The study was conducted on cultured *Acipenser ruthenus* and *Acipenser brevirostrum*. To our knowledge, we are the first to describe Hassall's corpuscles (HC) in the thymic medulla in three out of 16 investigated fish. Fänge (1986) in his overview of the lymphoid organs in sturgeons, performed his study on Pacific white sturgeon (*Acipenser transmontanus*) and young hybrid sturgeons (*Huso x Acipenser ruthenus*) and noted no Hassall's corpuscles.

In our study, we detected premature and juvenile type of HC; all tested fish were juveniles not older than 19 months. Physiologically, the number of HC is rising with increasing age and is connected with a thymic atrophy. An increased number of HC in juveniles is often caused by the prolonged stress or chronic disease. In these cases, mature and senescent types of HC are more frequently present (Salkova and Flajshans, 2016). Such finding may serve as an indicator of the pathological condition.

The fact that HC were seen only in a minority of tested sturgeons may be explained by the low age and a favourable, healthy environmental conditions in recirculating aquaculture system.

Our finding completes the missing information about HC occurrence and contributes to the complete histological description of the thymus.

In our second study, the morphological mapping of the thymic microenvironment in sterlet (*Acipenser ruthenus*) was extended by applying an immunohistochemical examination (Salkova et al., 2020). Immunohistochemistry (IHC) is a method used to determine the antigen expression in tissues and organs using antibodies (Ramos-Vara, 2005; Taylor and Rudbeck, 2013). The antigens are localized in the different cell compartments, i.e. on the cell membrane, in the cytoplasm and in the nucleus. Most commercially available antibodies are of mammalian origin (i.e., mouse, rabbit, or goat) and primarily intended and targeted against

human cells and tissues. Monoclonal antibodies bind to a single epitope of an antigen, and thus provide high specificity. On the other hand, polyclonal antibodies contain antibodies against a wide range of epitopes (Jones et al., 1993; Ramos-Vara, 2005; Taylor and Rudbeck, 2013; Ramos-Vara and Miller, 2014). Thus, their specificity may be lower, and sensitivity higher compared to monoclonal antibodies. Greater nonspecific background staining may be present using polyclonal antibodies and cross-reactivity may be found in cases when target tissue antigen epitopes are shared with other proteins. Knowing the proper antigen setting, including the location of positive reaction patterns is important for interpreting the results obtained (Ramos-Vara, 2005; Taylor and Rudbeck, 2013).

Immunohistochemical examination includes three basic steps: pre-analytic, analytic, and post-analytic. The pre-analytic step comprises tissue sampling, tissue processing with appropriate fixation and paraffin embedding, block cutting and slide preparation. The analytic phase consists of reactions between antigens and antibodies and the visualization of such complexes. The post-analytic step includes result evaluation and interpretation (Ramos-Vara, 2005; Ramos-Vara et al., 2008; Taylor and Rudbeck, 2013).

Though IHC application in veterinary medicine continues to rise, especially in the last decades, it is still less commonly used compared to human medicine and pathology. Lack of species-specific antibodies is one obstacle (Ruiz et al., 2005; Ramos-Vara et al., 2008). In veterinary medicine, most reported cases describe markers investigation using commercially available antibodies routinely used in human medicine (Gallo et al., 2004; Jorgensen et al., 2009; Tarakci et al., 2012; Dezfuli et al., 2014; Paquette et al., 2015; Yasumoto et al., 2015). A small number of antibody sets is produced and manufactured by researchers themselves (Pan et al., 2000; Dezfuli et al., 2014; Jorgensen et al., 2009).

Cases of IHC application in veterinary medicine have most often involved mammals. Ruiz et al. (2005) in their study tested tissues of mammalian origin (dog, monkey, bear *Ursus arctos middendorffi*, bovine) with a panel of 21 different markers using 26 different antibodies on a set of nine neoplastic, one reactive and one normal tissue. The antibodies applied in the study were commercially available and originally intended for use in human medicine. The majority of investigated cases showed positivity, only two of twenty-six (2/26) antibodies did not react on tissue sections. This study confirmed that many of the antibodies produced for use in human medicine may be applied in Veterinary Medicine. Ramos-Vara et al. (2008) made an extensive study and survey on immunohistochemistry in veterinary practise and suggested guidelines for IHC in veterinary diagnostic laboratories. Most cases were tested on mammalian tissues. Each step in the IHC process from tissue sampling to result interpretation was described, common difficulties in veterinary practise were cited and a proposal of how to deal with the problems was made. Validation, standardization, and quality assurance/quality control was designed.

Immunohistochemistry in fish is still quite rare, compared to other animal species. There are physiological studies mapping antigen distributions and setting on different cell types and tissues (e.g., Pan et al., 2000 in stomachless teleost fish). Mohammad et al. (2007) performed immunohistochemical examination of thymic epithelial cells in Australian lungfish (*Neoceratodus forsteri*). Gallo et al. (2004) performed immunohistochemical mapping of the chromaffin system in beluga sturgeon (*Huso huso*). Tarakci et al. (2012) provided a study mapping the distribution of endocrine cells in the stomach of endemic trout *Salmo macrostigma* (mountain trout *Salmo trutta macrostigma*).

Immunohistochemistry also serves as an important and powerful investigative tool in the differential diagnosis of pathologies, including infectious diseases (Dezfuli et al., 2014 in perch *Perca fluviatilis*; Jorgensen et al., 2009 in rainbow trout *Oncorhynchus mykiss*; Orós et al., 2014 in reptiles including various snakes, sea turtles and lizards) or neoplastic lesions.

Immunohistochemistry confirms the origin of the neoplastic lesions: canine neoplastic lesions were investigated by Ciaputa et al. (2016) in mixed-breed dogs; Kim et al. (2015) in Maltese dog; Kim et al. (2016) in Golden Retriever; Macrii et al. (2015) in German Shepherd inbred; Park et al. (2016) in Maltese dog. Feline neoplastic lesions were examined by Aslan et al. (2014) in Siamese cat; Filho et al. (2015) in Persian cat. Avian neoplastic lesions were studied by Timurkaan et al. (2016) in budgerigar (*Melopsittacus undulatus*) and ichthyological neoplastic lesions were tested by Iaria et al. (2019) in four fish tumours; by Paquette et al. (2015) in zebra fish, by Sirri et al. (2010) and by Yasumoto et al. (2015) both in common carp. The IHC results and their interpretation are important for treatment decisions and may also lead to subsequent targeted therapy as documented by Kim et al. (2016) in mast cells tumours in Golden Retrievers.

The aim of our second study was to examine the specificity and sensitivity of various immunohistochemical markers in juvenile sterlet (*Acipenser ruthenus*). We tested a panel of commercially available antibodies routinely used in human medicine to describe thymic components. Wide range cytokeratin, vimentin, S-100 protein, LCA (CD45) and CD3 were applied, discussion of the results obtained was provided. Examination of wide range cytokeratin (cytokeratin AE1/AE3), vimentin and S-100 protein was successful, and the results obtained were positive and conclusive. Our study confirmed the possibility of commercially available human antibody application on fish tissue. In addition, examination of LCA (CD45) and CD3 was negative as the antibody did not react with the antigen or the final result showed cross-reactivity. Thus, negative, or inconclusive results respectively, support the importance of generating fish specific antibodies. The application of IHC in fish may contribute to more comprehensive knowledge of antigen settings under specific physiological conditions. Immunohistochemistry (IHC) thus provides supplemental information to routine histological assessment.

---

### Haematology of polyploid sturgeons

Sturgeons exhibit large genomes among fishes (Gregory and Witt, 2008; Smith and Gregory, 2009) and these are well known for their polyploidy origin. Acipenseriformes have a high tolerance for hybridization as well as for spontaneous doubling of chromosome sets (autopolyploidization) (Havelka et al., 2016). It is worth noting that among vertebrates, sturgeons exhibit the second highest chromosome count (Havelka et al., 2016). Cell and nuclear size both correlate strongly with genome size and with each other in ray-finned and cartilaginous fishes. These relationships remain significant at each taxonomic level and exist independently of phylogeny (Hardie and Hebert, 2003). The chromosome number positively correlates with DNA content among fishes (Smith and Gregory, 2009). Increased cellular and nuclear volume due to the additional chromosomal set or sets is balanced by reduced cell numbers (Benfey, 1999; Maxime, 2008).

In our study, we examined white blood cell parameters on different ploidy level cultured sturgeons. *Acipenser ruthenus* was a functionally diploid (2n) representative, *Acipenser gueldenstaedtii* represented the functionally tetraploid (4n) group and *Acipenser brevirostrum* the hexaploid group (6n). Our study involved annual haematological examination of juvenile representatives cultured in a recirculating aquaculture system (RAS) under stable conditions over a period of one year. The total number of leukocytes and differential leukocyte counts were established, and the data obtained were statistically evaluated (manuscript under revision in Veterinary Medicine). In our study, no blasts were present in blood smears and vanishing cells were not involved in differential counts. Vanishing cells were usually present as cells with disintegrated cell membrane, “ghost” nuclei or just as clusters of remaining

cytoplasmic granules (originating from vanishing eosinophils). Such cells should not be classified as distinct white blood cells (eosinophils, or neutrophils). Moreover, the number of nuclear segments would not be possible to assess in these vanishing elements.

In our study, we did not provide further division to myelocytes and metamyelocytes. Bands as younger forms and segments as developmentally matured cells were only distinguished.

It is worth noting that some scientists still encountered thrombocytes and thrombocyte-like cells within differential counts of leukocytes (Knowles et al., 2006; Zexia et al., 2007). Nowadays, thrombocytes are believed to belong to an individual blood cell category (Khandekar et al., 2012; Svobodova et al., 2012) with unique function and origin.

The total number of leukocytes (TL) was  $40.9317.24 \times 10^9/L$  for diploids,  $20.6311.20 \times 10^9/L$  for tetraploids,  $14.137.72 \times 10^9/L$  for hexaploids. TL decreased with increasing ploidy level. The highest number of leukocytes was reached during September and October for *A. ruthenus* and *A. brevirostrum*, from October to January for *A. gueldenstaedtii* (statistically significant finding). Lymphocytes dominated (76.89–80.14%) in differential counts and were found to be reduced in June and July in each group. Granulocytes were represented by neutrophils and eosinophils. Out of all the leukocytes, neutrophils represented 13.0–18.7% and eosinophils 5.7–6.1%, respectively. Increasing number of nuclear segments in granulocytes was dependent on increasing ploidy level. Nuclear segmentation in lymphocytes was a common finding in higher ploidy level groups. Data suggest the significant effect of ploidy level on the total number of leukocytes and morphological nuclear changes in granulocytes and lymphocytes. Annual variation in differential leukocyte counts depends on the species and various external conditions rather than ploidy level. Thus, knowledge of seasonal changes in white blood cell parameters should be considered when performing haematological examinations.

Available haematological data of annual and seasonal changes in blood cell parameters are scarce, especially for sturgeons, and have concentrated mostly on red blood cells. Results of our study should complete our basic knowledge regarding sturgeon haematology and physiology, respectively. Discussion regarding white blood cell parameters within representatives of particular ploidy level groups is presented and summarized. Comparison of species was performed upon the functional ploidy level scale (Havelka et al., 2011).

Examination of white blood cell parameters (total number of leukocyte and differential count), as well as histological and immunohistochemical examination, respectively, represent the main methodical approaches for lymphoid organ and immune system assessment in sturgeons. Methods should be applied in ichthyological practise. The results obtained should contribute to fish health status evaluation.

## References

- Aslan, O., Cakir, L., Bekdik, I.K., Dogan, Z., Tunc, A.C., 2014. Cholangiocarcinoma of intrahepatic bile ducts with disseminated metastases in a Siamese cat: a case report. *Vet. Med.* 59, 359–367.
- Benfey, T.J., 1999. The physiology and behaviour of triploid fishes. *Rev. Fish. Sci.* 7, 36–67.
- Ciaputa, R., Bandoch, P., Lewandowska, K., Madej, J.A., Kandefer-Gola, M., Janus, I., Nowak, M., 2016. Immunohistochemical analysis of metastasising hepatocellular carcinomas in dogs. *Vet. Med.* 61, 546–552.
- Dezfuli, B.S., Giari, L., Lorenzoni, M., Manera, M., Noga, E.J., 2014. Perch liver reaction to *Triaenophorus nodulosus* plerocercoids with an emphasis on piscidins 3, 4 and proliferative cell nuclear antigen (PCNA) expression. *Vet. Parasitol.* 200, 104–110.
- Fänge, R., 1986. Lymphoid organs in sturgeons (Acipenseridae). *Vet. Immunol. Immunopathol.* 12, 153–161.
- Filho, S.J.G., Magalhaes, G.M., Conforti, V.A., Santilli, J., Calazans, G.S., 2015. Biphasic pericardial and pleural mesothelioma in a cat: a case report. *Vet. Med.* 60, 105–108.
- Gallo, V.P., Accordi, F., Ohlberger, J., Civinini, A., 2004. The chromaffin system of the beluga sturgeon *Huso huso* (Chondrostei): Histological, immunohistochemical and ultrastructural study. *Ital. J. Zoolog.* 71, 279–285.
- Gregory, T.R., Witt, J.D.S., 2008. Population size and genome size in fishes: a closer look. *Genome* 51, 309–313.
- Havelka, M., Kaspar, V., Hulak, M., Flajshans, M., 2011. Sturgeon genetics and cytogenetics: a review related to ploidy levels and interspecific hybridization. *Folia Zoologica* 60, 93–103.
- Havelka, M., Bytyutskiy, D., Symonova, R., Rab, P., Flajshans, M., 2016. The second highest chromosome count among vertebrates is observed in cultured sturgeon and is associated with genome plasticity. *Genet Sel Evol.* 48, 1–9.
- Iaria, C., Ieni, A., Corti, I., Puleio, R., Brachelente, C., Mazzullo, G., Lanteri, G., 2019. Immunohistochemical study of four fish tumors. *J. Aquat. Anim. Health* 31, 97–106.
- Jones, M., Cordell, J.L., Beyers, A.D., Tse, A.G., Mason, D.Y., 1993. Detection of T and B cells in many animal species using cross-reactive anti-peptide antibodies. *J. Immunol.* 150, 5429–5435.
- Jorgensen, T.R., Raida, M.K., Kania, P.W., Buchmann, K., 2009. Response of rainbow trout (*Oncorhynchus mykiss*) in skin and fin tissue during infection with a variant of *Gyrodactylus salaris* (Monogenea: Gyrodactylidae). *Folia Parasitica* 56, 251–258.
- Khandekar, G., Kim, S., Jagadeeswaran, P., 2012. Zebrafish thrombocytes: Functions and Origins. *Adv. Hematol.* 2012. doi: 10.1155/2012/857058.
- Kim, J.H., Kim, H.J., Kim, D.H., Yim, J.H., Lee, S.J., Park, K.H., Yoon, H.Y., 2016. Successful response to imatinib in two dogs with inoperable grade III infiltrating mast cell tumours: a case report. *Vet. Med.* 61, 467–47.
- Kim, H. J., Choi, E.J., Lee, H.R., Park, G.J., Yun, E.S., Kim, J.H., Do, S.H., 2015. Spindle cell lipoma in the gingiva of a dog: a case report. *Vet. Med.* 60, 336–340.
- Knowles, S., Hrubec, T.C., Smith, S.A., Bakal, R.S., 2006. Hematology and plasma chemistry reference intervals for cultured shortnose sturgeon (*Acipenser brevirostrum*). *Vet. Clin. Pathol.* 35, 434–440.

- Macri, B., Lanteri, G., Capucchio, M.T., Ieni, A., Marino, F., 2015. A cystadenoma of the biliary ducts in a dog: anatomico-histopathological features and pathogenetic considerations: a case report. *Vet. Med.* 60, 288–291.
- Manca, R., Glomski, C.A., Pica, A., 2019. Hematopoietic stem cells debut in embryonic lymphomyeloid tissues in elasmobranch. *Eur. J. Histochem.* 63, 178–187.
- Mattisson, A., Fänge, R., 1982. The cellular structure of the Leydig organ in the shark, *Etmopterus spinax* (L.). *The Biological Bulletin* 162, 182–194.
- Maxime, V., 2008. The physiology of triploid fish: current knowledge and comparison with diploid fish. *Fish. Fish.* 9, 67–78.
- Mohammad, M.G., Chilmoneczyk, S., Birch, D., Aladaileh, S., Raftos, D., Joss, J., 2007. Anatomy and cytology of the thymus in juvenile Australian lungfish, *Neoceratodus forsteri*. *J. Anat.* 211, 784–797.
- Orós, J., Arencibia, A., Jensen, H.E., 2014. Immunohistochemistry as a tool for the accurate diagnosis of diseases in reptiles. *Formatex. Microscopy: advances in scientific research and education*, pp. 311–319.
- Pan, Q.S., Fang, Z.P., Zhao, Y.X., 2000. Immunocytochemical identification and localization of APUD cells in the gut of seven stomachless teleost fishes. *World J. Gastroenterol.* 6, 96–101.
- Paquette, C.E., Kent, M.L., Peterson, T.S., Wang, R., Dashwood, R.H., Löhr, C.V., 2015. Immunohistochemical characterization of Intestinal Neoplasia in Zebrafish (*Danio rerio*) indicates epithelial origin. *Dis. Aquat. Org.* 116, 191–1917.
- Park, J. K., Lee, E.M., Kim, A.Y., Lee, E.J., Hong, I.H., Ki, M.R., Jeong, K.S., 2016. Alveolar rhabdomyosarcoma in a dog confirmed using myogenin immunohistochemistry: a case report. *Vet. Med.* 61, 267–271.
- Peng, Z., Ludwig, A., Wang, D., Diogo, R., Wei, Q., He, S., 2007. Age and biogeography of major clades in sturgeons and paddlefishes (Pisces: Acipenseriformes). *Mol. Phylogenet. Evol.* 42, 854–862.
- Ramos-Vara, J.A., 2005. Technical aspects of immunohistochemistry. *Vet. Pathol.* 42, 405–426.
- Ramos-Vara, J.A., Kiupel, M., Baszler, T., Bliven, L., Brodersen, B., Chelack, B., Czub, S., Del Piero, F., Dial, S., Ehrhart, E.J., Graham, T., Manning, L., Paulsen, D., Valli, V.E., West, K., 2008. Suggested guidelines for immunohistochemical techniques in veterinary diagnostic laboratories. *Journal of Veterinary Diagnosis and Investigation* 20, 393–413.
- Ramos-Vara, J.A., Miller, M.A., 2014. Antigens and antibodies get along: Revisiting the technical aspects of immunohistochemistry – the red, brown and blue technique. *Vet. Pathol.* 51, 42–87.
- Ruiz, F.S., Alessi, A.C., Chagas, C.A., Pinto, G.A., Vassallo, J., 2005. Immunohistochemistry in diagnostic veterinary pathology: a critical review. *Jornal Brasileiro de Patologia e Medicina Laboratorial.* 41, 263–270.
- Salkova, E., Flajshans, M., 2016. The first finding of Hassall's corpuscles in the thymi of cultured sturgeons. *Vet. Med.* 61, 464–466.
- Salkova, E., Flajshans, M., Steinbach, C., 2020. Immunohistochemical mapping of thymic microenvironment in sterlet (*Acipenser ruthenus*). *Vet. Med.* 65, 301–308.
- Scharrer, E., 1944. The histology of the meningeal myeloid tissue in ganoids *Amia* and *Lepisosteus*. *The Anatomical Record* 88, 291–297.



- Sirri, R., Mandrioli, L., Grieco, V., Bacci, B., Brunett, B., Sarli, G., Schmidt-Posthaus, H., 2010. Seminoma in a koi carp *Cyprinus carpio*: histopathological and immunohistochemical findings. *Dis. Aquat. Org.* 92, 83– 88.
- Smith, E.M., Gregory, T., 2009. Patterns of genome size diversity in the ray-finned fishes. *Hydrobiologia.* 625, 1–25.
- Svobodova, Z., Pravda, D., Modra, H., 2012. Unified methods of fish haematological investigations. RIFCH Vodnany, Edition of Methods, No. 122. 29 pp. (in Czech)
- Tarakci, G.B., Bayrakdar, A., Yaman, M., 2012. Immunohistochemical study of the endocrine cells in the stomach and pyloric caeca of the mountain trout, *Salmo trutta macrostigma*. *Iran. J. Fish. Sci.* 11, 776–785.
- Tavassoli, M., 1986. Bone marrow in boneless fish: lessons of evolution. *Med. Hypotheses.* 20, 9–15.
- Taylor, C.R., Rudbeck, L., 2013. Immunohistochemical staining methods. IHC Guidebook, Dako, 6<sup>th</sup> edition.
- Timurkaan, N., Eroksuz, H., Cevik, A., Karabulut, B., 2016. Cutaneous leiomyosarcoma with osteoid metaplasia in a budgerigar (*Melopsittacus undulatus*): a case report. *Vet. Med.* 61, 533–537.
- Volff, J. N., 2005. Genome evolution and biodiversity in teleost fish. *Heredity.* 94, 280–294.
- Yasumoto, S., Koga, D., Tanaka, K., Kondo, M., Takahashi, Y., 2015. Histopathological and immunohistochemical studies of gonadal undifferentiated carcinoma in common carp *Cyprinus carpio*. *Fish Pathol.* 50, 53–59.
- Zexia, G., Weimin, W., Yi, Y., Abbas, K., Dapeng, L., Guiwei, Z., Diana, J.S., 2007. Morphological studies of peripheral blood cells of the Chinese sturgeon, *Acipenser sinensis*. *Fish Physiol. Biochem.* 33, 213–222.

**Methodical approaches to examination of lymphoid tissues in sturgeons**

Eva Šálková

Sturgeons live on Earth for a long period of time, acipenseriform fishes first appeared already during Jurassic period, as it has been documented from fossil records. Well-developed immune system enabled sturgeons to face and deal with different attacks (e.g. infections, stress, external environmental conditions), and thus played an important and crucial role in sturgeon survival until present days. Sturgeons exhibit large genomes among fishes and are well known for their polyploidy origin. Acipenseriformes have a high tolerance for hybridization as well as for spontaneous doubling of chromosome sets (autopolyploidization). In their evolution, at least three independent polyploidization events have taken place, in the literature known as 3R hypothesis (three rounds hypothesis). It is worth noting, that among vertebrates, sturgeons exhibited second highest chromosome count.

Therefore, the present research focused on the haematopoietic and lymphoid tissues examination. Representatives of different ploidy level groups were encountered in the study: sterlet (*Acipenser ruthenus*) represented diploid (2n) group, Russian sturgeon (*Acipenser gueldenstaedtii*) was chosen as tetraploid group representative (4n), and finally shortnose sturgeon (*Acipenser brevirostrum*) served as hexaploid group representative (6n).

Haematopoietic and lymphoid tissues were conventionally histologically processed, obtained sections were stained using haematoxylin and eosin. Advanced histological staining methods were applied when examining tissues to map and recognize particular cell types involved in haemato- and lymphopoiesis (Giemsa staining, PAS staining, Perls reaction, alcian blue). Hassall's corpuscles were detected in thymi, particular in the thymic medulla; to our knowledge, it was the first description of Hassall's corpuscles in sturgeons.

Subsequently, the thymus of juvenile sterlet (*Acipenser ruthenus*) was examined immunohistochemically. The wide range cytokeratin, vimentin, S-100 protein, leukocyte common antigen LCA (CD45) and CD3 were selected as the markers to map the thymic microenvironment. Commercially available human antibodies were applied on fish tissue, and wide range cytokeratin, vimentin, S-100 protein brought conclusive results and distinguished nature of different microenvironmental components. Contrarily, LCA and CD3 application was negative or inconclusive, and failed. Study confirmed the possibility of human antibody application on fish tissue, together with the need to generate fish and species-specific antibodies, mostly when examining lymphoid tissues.

Except for the histological and immunohistochemical examination, respectively, the lymphoid or immune system should be tested when using the determination of white blood cell parameters. Generally, the blood is more easily accessible (vessel puncture), and the determination of the total number of leukocytes and the differential counts represent important fish health and physiology status.

Under the study, representatives of three different ploidy level groups were tested and white blood cell parameters were monitored monthly during a period of one year. Data suggested the significant effect of ploidy level on total number of leukocytes and morphological nuclear changes in granulocytes and lymphocytes. Annual variation in differential leukocyte counts depended on the species and influence of various external conditions rather than ploidy level.

Examination of white blood cell parameters (total number of leukocyte and differential count), as well as histological and immunohistochemical examination, respectively, represent the main methodical approaches for lymphoid organs and immune system assessment in sturgeons. Methods should be applied and available in an ichthyological practise. Obtained results contribute to fish health status evaluation.

## Czech summary

**Metodické přístupy k vyšetření lymfoidních tkání jeseterů**

Eva Šálková

Jeseteři se na Zemi vyskytují již více než 200 milionů let, jak dokládají fosilní nálezy pocházející z období Jury. Přežití do současnosti jim umožnil dobře vyvinutý a fungující obranný systém, zajišťující odolnost vůči mnohým zevním faktorům (např. podmínky zevního prostředí, infekce, různé stresové situace).

Jeseteři jsou známí poměrně velkým genomem a náchylností k polyploidizačním událostem. Mezi obratlovci jsou pak uváděni jako zástupci s druhým nejvyšším doloženým počtem chromosomů. Je známo, že v evoluci jeseterovitých ryb se uskutečnily tři celogenomové duplikace, označované jako 3R hypotéza (3 rounds hypothesis). Na základě této znalosti je možno jeseterovité ryby členit do různých ploidních skupin, s tím pak souvisí i rozdílné počty chromozómů u jednotlivých zástupců.

V naší práci jsme se zaměřili na vyšetření hematopoetické a lymfoidní tkáně u jeseterů. Studie byly prováděny na zástupcích jednotlivých ploidních úrovní: jeseter malý (*Acipenser ruthenus*) byl vybrán jako zástupce diploidní skupiny (2n), jeseter ruský (*Acipenser gueldenstaedtii*) jako zástupce tetraploidní (4n) a jeseter krátkorýpý (*Acipenser brevirostrum*) jako představitel hexaploidní skupiny jeseterů (6n).

U jesetera malého (*Acipenser ruthenus*) a jesetera krátkorýpého (*Acipenser brevirostrum*) jsme provedli histologické vyšetření hematopoetických a lymfoidních tkání. Tkáně byly klasicky zpracovány a obarveny hematoxylinem a eosinem. K bližšímu určení jednotlivých typů hematopoetických a lymfoidních buněk jsme použili další histologická barvení, a to především barvení dle Giemsy, barvení metodou PAS, alcianovou modří a reakci na průkaz železa (Perlsova reakce). Při vyšetření thymu jsme ve dřeni objevili Hassalova tělíska. Podle dostupných informací je naše sdělení považováno za první popis Hassalových tělísek v thymu jeseterů.

Následovala studie, která se zabývala imunohistochemickým vyšetřením thymu juvenilního jesetera malého. K vyšetření jsme použili komerčně dostupné protilátky běžně používané v humánní medicíně a diagnostice. Pro mapování thymického mikroprostředí jsme použili širokospektrý cytokeratin, vimentin, S-100 protein, leukocyte common antigen (LCA, CD45), CD3. Pozitivní výsledky jsme zaznamenali při vyšetření širokospektrého cytokeratinu, vimentinu a S-100 proteinu, zatímco vyšetření LCA a CD3 přineslo negativní nebo neprůkazné výsledky. Získané výsledky ukazují na možnost použití některých komerčně dostupných protilátek při vyšetřování tkání ryb, zároveň však poukazují na nutnost vývoje druhově a tkáňově specifických rybích protilátek (převážně u lymfoidních markerů).

Hematologické vyšetření, především pak stanovení parametrů bílého krevního obrazu, představuje další z přístupů umožňující zkoumání a posouzení lymfoidních tkání u jeseterů. Odběr krve je, ve srovnání s potřebou tkání pro histologické vyšetření, technicky jednodušší, dostupnější pro vyšetření. Stanovení celkového počtu bílých krvinek a diferenciálního rozpočtu pak přináší důležité ukazatele celkového zdravotního stavu ryb.

Naše studie se zaměřila na sledování parametrů bílého krevního obrazu a jejich změn v průběhu jednoho roku u zástupců tří různých ploidních úrovní jeseterů. Měsíčně jsme u deseti jedinců různých ploidních úrovní vyšetřili parametry bílého krevního obrazu. Získaná data ukázala, že ploidní úroveň ovlivňuje celkový počet leukocytů a podílí se na morfologických jaderných změnách granulocytů a lymfocytů. Naopak sezónní změny bílého krevního obrazu jsou závislé více na druhu jesetera a vlivech vnějšího prostředí než na ploidní úrovni.

Vyšetření bílého krevního obrazu (stanovení celkového počtu leukocytů a diferenciálního rozpočtu) a histologické vyšetření tkání, a to včetně technicky náročnější imunohistochemie, představuje hlavní metodické přístupy při posuzování lymfoidních orgánů a imunitního stavu jeseterů. Metody mohou být používány v ichtyologických laboratořích a výstupy jednotlivých vyšetření představují důležité ukazatele při posuzování celkového zdravotního stavu ryb.

## **Acknowledgements**

First of all, I would like to express my deep gratitude to my supervisor Prof. Martin Flajšhans for his guidance, overall support, patience, willingness, advices and comments during my study. I appreciate his vast amount of knowledge, expertise, constructive criticism, which considerably helped enrich my graduate experience. I appreciate his kindness, and warm heart attitude. It was an honour and pleasure for me to study and work under his supervision.

I would like to thank to all staff from the Laboratory of Molecular, Cellular and Quantitative Genetics and David Gela from Genetics Fisheries Center of the Faculty of Fisheries and Protection of Waters in Vodňany, who helped me with my experiments and lab work. Special thanks belong to Marie Pečená who was giving me tremendous help with technical aspects during the work and providing all the necessary facilities for my experiments. I would also like to thank to Jindřiška Procházková and Eliška Axmannová from the Department of Pathology and Molecular Medicine, 2<sup>nd</sup> Medical Faculty and Teaching Hospital in Motol in Prague for their valuable advises when providing and introducing histological and immunohistochemical examination.

I am grateful to my colleague, Christoph Steinbach, from the Laboratory of Aquatic Toxicology and Ichthyopathology for his kindness and technical support, especially with performing microphotography.

Last but not least, sincere thanks belong to my entire family, my husband, my children and of course my parents for their support, concern and strength through my life and my studies.

I also appreciate the financial support from the following projects that funded parts of the research discussed in this dissertation:

- Ministry of Education, Youth and Sports of the Czech Republic – projects „CENAKVA“ (No. CZ.1.05/2.1.00/01.0024), “CENAKVA II” (No. LO1205 under the NPU I program), and Biodiversity (CZ.02.1.01/0.0/0.0/16\_025/0007370).
- Czech Science Foundation – projects No. 14-02940S and 18-09323S.

## List of publications

### Peer-reviewed journals with IF

Sancho Santos, M.E., **Salkova, E.**, Horky, P., Steinbach, C., 2021. Comment on “Diluted concentrations of methamphetamine in surface water induce behaviour disorder, transgenerational toxicity, and ecosystem-level consequences of fish by Zhenglu Wang, Kang Mao, Wei Du, Min Cai, Zhaobin Zhang, Xiqing Li [Water Research 184 (2020) 116–164]”. *Water Research*, available online, March 25<sup>th</sup>, 117007. (IF 2020 = 11.236)

**Salkova, E.**, Flajshans, M., Steinbach, C., 2020. Immunohistochemical mapping of the thymic microenvironment in sterlet (*Acipenser ruthenus* L.). *Veterinarni Medicina* 65, 301–308. (IF 2019 = 0.588)

Sancho Santos, M.E., Grabicova, K., Steinbach, C., Schmidt-Posthaus, H., **Salkova, E.**, Kolarova, J., Vojs Stanova, A., Grabic, R., Randak, T., 2020. Environmental concentration of methamphetamine induces pathological changes in brown trout (*Salmo trutta fario*). *Chemosphere* 254, 1–13. (IF 2019 = 7.086)

**Salkova, E.**, Flajshans, M., 2016. The first finding of Hassall’s corpuscles in the thymi of cultured sturgeons. *Veterinarni Medicina* 61, 464–466. (IF 2015 = 0.560)

### Manuscripts

**Salkova, E.**, Gela, D., Pecherkova, P., Flajshans, M., 2021. Examination of white blood cell parameters for three different ploidy level sturgeon species reared in an indoor recirculation aquaculture system for one year. Manuscript

### Abstracts and conference proceedings

**Salkova, E.**, Gela, D., Pecherkova, P., Flajshans, M., 2020. Examination of white blood cell parameters for three different ploidy level sturgeon species reared in an indoor recirculation aquaculture system for one year. In: Book of abstracts “ XVII. Rybářská a ichtyologická konference”, November 4<sup>th</sup>–5<sup>th</sup> 2020, on-line conference, Vodňany, Czech Republic, p. 5.

**Salkova, E.**, Tumova, J., Flajshans, M., 2018. Immunohistochemical examination in fish, results of pilot study. In “ XVI. Rybářská a ichtyologická konference”, October 10<sup>th</sup>–11<sup>th</sup> 2018, Brno, Czech Republic, p. 94.

**Salkova, E.**, Flajshans, M., 2016. First finding of Hassall’s corpuscles in the thymi of cultured sturgeons. In “XV. Rybářská a ichtyologická konference”, February 4<sup>th</sup>–5<sup>th</sup> 2016, Prague, Czech Republic, p. 58.

**Training and supervision plan during the study**

<b>Name</b>	Eva Šálková
<b>Research department</b>	2012–2021: Laboratory of Molecular, Cellular and Quantitative Genetics, FFWP
<b>Supervisor</b>	Prof. Martin Flajšhans
<b>Period</b>	1 <sup>st</sup> October 2012 until 15 <sup>th</sup> September 2021
<b>Ph.D. courses</b>	
English	2013
Ichthyology and fish systematics	2013
Applied hydrobiology	2013
Histology and cytology of fish	2013
Pond aquaculture	2015
<b>Scientific seminars</b>	
Seminar days of RIFCH and FFPW	2013
	2014
	2015
	2016
<b>National conferences</b>	
Salkova, E., Gela, D., Pecherkova, P., Flajshans, M., 2020. Examination of white blood cell parameters for three different ploidy level sturgeon species reared in an indoor recirculation aquaculture system for one year. In: Book of abstracts " XVII. Rybářská a ichtyologická konference", November 4 <sup>th</sup> –5 <sup>th</sup> 2020, on-line conference, Vodňany, Czech Republic, p. 5.	2020
Salkova, E., Tumova, J., Flajshans, M., 2018. Immunohistochemical examination in fish, results of pilot study. In " XVI. Rybářská a ichtyologická konference", October 10 <sup>th</sup> –11 <sup>th</sup> 2018, Brno, Czech Republic, p. 94.	2018
Salkova, E., Flajshans, M., 2016. First finding of Hassall's corpuscles in the thymi of cultured sturgeons. In " XV. Rybářská a ichtyologická konference", February 4 <sup>th</sup> –5 <sup>th</sup> 2016, Prague, Czech Republic, p. 58.	2016

**Curriculum vitae****PERSONAL INFORMATION**

**Name:** Eva  
**Surname:** Šálková  
**Maiden name:** Veselá  
**Title:** M.D.  
**Born:** 26<sup>th</sup> July, 1980, Strakonice, Czech Republic  
**Nationality:** Czech  
**Languages:** Czech, English (B2 level – FCE certificate), German, Hungarian (basic), Latin (script only)  
**Contact:** pat.vesela.eva@email.cz

**EDUCATION**

**2012–present** Ph.D. student in Fishery, Faculty of Fisheries and Protection of Waters, University of South Bohemia, České Budějovice, Czech Republic

**2009** Licence in Surgical Pathology

**1998–2004** 1<sup>st</sup> Medical Faculty, Charles University, Prague, M.D.

**1993–1998** Secondary Grammar School, Písek

**PROFESSIONAL CAREER**

**2004–2020** Motol University Hospital and Charles University in Prague, Department of Pathology and Molecular Medicine, pathologist

**2020–present** CGOP Laboratory of Pathological Anatomy, Prague, head of the laboratory

**PH.D. COURSES** Ichthyology and fish systematics, Applied hydrobiology, Pond aquaculture, Histology and cytology of fish, English language

**COMPLETED COURSES**

**2015** Fish histopathology, especially in toxicological studies – focus on trout and carp, FFPW, University of České Budějovice, Vodňany, Czech Republic

**2018** Fish histopathology – possibilities and limitations, FFPW, University of České Budějovice, Vodňany, Czech Republic



