

**Czech University of Life Sciences Prague**

**Faculty of Agrobiography, Food and Natural Resources**

**Department of Veterinary Sciences**



**Czech University  
of Life Sciences Prague**

**Oncological Diseases in Rabbits**

**Bachelor's Thesis**

**Zuzana Repková, Dis.  
Exotic Animals Breeding**

**Mgr. Ing. Tereza Krejčová Ph.D.**

**© 2024 CZU in Prague**

## **Declaration**

I hereby declare that I have authored this bachelor's thesis carrying the name "Oncological Diseases in Rabbits" independently under the guidance of my supervisor. Furthermore, I confirm that I have used only professional literature and other information sources that have been indicated in the thesis and listed in the bibliography at the end of the thesis. As the author of the bachelor's thesis, I further state that I have not infringed the copyrights of third parties in connection with its creation.

In Prague on 10.04.2024

---

## **Acknowledgments**

I would like to express my sincere gratitude to my supervisor, Mrs. Tereza Krejčová, for her constant support and guidance in the preparation of this work. I am also very grateful to Mrs. Martina Frühauf Kolářová for discussing the rabbit issue.

I express my great thanks to Dr. Scott MacPherson and my family for their support. I also thank those who enriched my work with case studies.

I would like to thank my beloved rabbit Franz Josef I and honour his memory with this work. Additionally, in memory of all the rabbits who suffered from cancer.

# Oncological Diseases in Rabbits

## Summary:

Oncological diseases in rabbits (*Oryctolagus*) are gradually becoming more and more common. This is due to the growing popularity of breeding rabbits as pets and as a result, rabbits are living longer. Oncological diseases arise based on genetic mutations of specific genes. Mutations in proto-oncogenes and tumour suppressor genes are responsible for causing cancer. The immune system reacts to the occurrence of cancer cells, but it is not efficient enough and later fails in the fight with these cells, resulting in cancer.

Predisposing factors in rabbits include heredity, sex, breed and especially age. If the presence of a tumour is detected early, the prognosis can be good. However, symptoms are usually not present in rabbits; thus, the diagnosis is often made only at an advanced stage of the disease, when the possibilities of therapy are already very limited. Various advanced diagnostic methods can be used for diagnostic examination, most often a sonography or X-ray, but this is quite stressful for rabbits. Often, the diagnosis is made only at an advanced stage of the oncological disease, which is unfortunately fatal for the rabbit due to the occurrence of metastases. To establish an accurate diagnosis, it is necessary to take a tissue sample for histological examination.

The therapy of oncological diseases in rabbits is not so widespread yet. Most often, as in humans, it is treated with chemotherapy or radiation. However, early surgery is the most effective treatment in rabbits.

The most frequent tumours in rabbits are adenocarcinomas of the uterus and mammary glands. That is why unneutered females at an older age are most often at risk. Other frequent types are lymphomas and thymomas. Each tumour is specific and has a different aggressiveness and associated prognosis.

Since oncology in rabbits has received little study, it is important to mention examples of benign tumours and inflammatory abscesses that are often confused with oncological tumours. The bachelor thesis is enriched by case studies of rabbits with an oncological diagnosis and with a diagnosis of inflammatory and benign tumours that were confused with cancer tumours.

Cancer treatment in rabbits is unsuccessful in most cases, and so far, most veterinarians are leaning towards euthanasia if the occurrence of metastases is evident.

**Keywords:** cancer, diagnosis, genetics, immunology, malignancy, mutations, rabbit, symptoms, treatment, tumour

## **Souhrn:**

Onkologická onemocnění se u králíků (*Oryctolagus*) nyní vyskytují mnohem častěji než dříve. Je to spojeno s větší popularitou chovu králíků jako domácích mazlíčků a díky tomu se králíci také dožívají vyššího věku. Onkologická onemocnění jsou u králíků nejčastěji podmíněna genetickými mutacemi specifických genů. Za vznik rakoviny jsou zodpovědné mutace proto-onkogenů a tumor supresorových genů. Imunitní systém reaguje na výskyt rakovinných buněk ale není dostatečně účinný v boji s těmito buňkami a rakovinné bujení se postupně rozvíjí.

K predispozičním faktorům u králíků řadíme dědičnost, pohlaví, plemeno a hlavně věk. Pokud je přítomnost nádoru zachycena včas, prognóza může být dobrá. Avšak králíci v počátečních fázích onkologického vývoje obvykle nevykazují žádné příznaky, a proto je často diagnóza stanovena až v pokročilém stádiu onemocnění, kdy i možnosti terapie již bývají velmi omezené. K diagnostickému vyšetření lze použít různé pokročilé diagnostické metody, nejčastěji sonografii nebo rentgen, ale to je pro králíky poměrně stresující záležitost. Často je tedy diagnóza stanovena až v pokročilém stádiu onkologického onemocnění a to je pro králíka z důvodu výskytu metastáz bohužel fatální. Pro stanovení přesné diagnózy je nutné i odebrat vzorek tkáně na histologické vyšetření.

Terapie onkologických onemocnění u králíků zatím není tolik rozšířena. Nejčastěji se, stejně jako u lidí, používá léčba chemoterapií nebo ozařováním. Včasná operace je však nejúčinnější léčbou u králíků.

Nejčastěji se vyskytujícími nádory u králíků jsou adenokarcinomy dělohy a mléčných žláz. Nejvíce jsou proto ohroženy nekastrované samice ve vyšším věku. Dalšími častými typy jsou lymfomy a thymomy. Každý nádor je specifický a vykazuje různou agresivitu a s tím spojenou prognózu.

Vzhledem k tomu, že je doposud onkologie u králíků málo prozkoumána, je důležité uvést, že u králíků může často docházet i k nezhojným nádorům a zánětlivým onemocněním, které se prezentují formou abscesů a mohou být snadno zaměňovány s onkologickými nádory. Bakalářská práce je obohacena o konkrétní kazuistiky králíků s onkologickou diagnózou a také s diagnózou zánětlivých a benigních tumorů, které byly s rakovinnými nádory zaměněny.

Léčba rakoviny u králíků je ve většině případů bohužel neúspěšná a zatím se veterináři spíše přiklání k eutanazii, pokud je patrný výskyt metastáz.

**Klíčová slova:** diagnóza, genetika, imunologie, králík, léčba, mutace, nádor, příznaky, rakovina, zhoubnost

# Content

<b>1</b>	<b>Introduction .....</b>	<b>1</b>
<b>2</b>	<b>Aims of the thesis .....</b>	<b>2</b>
<b>3</b>	<b>Literature review .....</b>	<b>3</b>
<b>3.1</b>	<b>Introduction to cancer .....</b>	<b>3</b>
<b>3.2</b>	<b>Cancer genetics.....</b>	<b>3</b>
3.2.1	Basics.....	3
3.2.2	Proto-oncogenes .....	4
3.2.3	Tumour suppressor genes .....	4
3.2.4	Peto's paradox .....	6
3.2.5	Mutations .....	6
3.2.5.1	Types of mutations in proto-oncogenes.....	6
3.2.5.2	Types of mutations in tumour suppressor genes.....	8
3.2.5.3	Epigenetics.....	9
<b>3.3</b>	<b>Cancer immunology.....</b>	<b>9</b>
3.3.1	Cancer stages .....	9
3.3.2	Types of cancer.....	10
3.3.3	Immune system function.....	11
3.3.4	Immunological response to cancer .....	11
<b>3.4</b>	<b>Predisposition .....</b>	<b>12</b>
<b>3.5</b>	<b>Clinical symptoms.....</b>	<b>14</b>
<b>3.6</b>	<b>Diagnosis .....</b>	<b>14</b>
<b>3.7</b>	<b>Treatment .....</b>	<b>15</b>
<b>3.8</b>	<b>Tumours in rabbits .....</b>	<b>16</b>
3.8.1	Uterine adenocarcinoma .....	16
3.8.2	Lymphoma.....	17
3.8.3	Thymoma.....	18
3.8.4	Leukaemia.....	18
3.8.5	Mammary adenocarcinoma .....	19
3.8.6	Testicular malignant tumours .....	20
3.8.7	Adrenal carcinoma.....	20
3.8.8	Sarcomas.....	20
3.8.8.1	Bone sarcomas .....	21
3.8.8.2	Liposarcoma and fibrosarcoma.....	22
3.8.8.3	Muscle sarcomas.....	22
3.8.8.4	Myxosarcoma .....	23
3.8.8.5	Hematopoietic sarcoma .....	23

3.8.9	Skin malignant tumours .....	23
3.8.10	Other primary neoplasia.....	24
<b>3.9</b>	<b>Oncological case studies.....</b>	<b>25</b>
3.9.1	Mammary carcinomas.....	25
3.9.2	Uterine adenocarcinomas.....	28
3.9.3	Sarcoma .....	29
<b>3.10</b>	<b>Differential diagnosis of tumours .....</b>	<b>30</b>
3.10.1	Benign tumours.....	31
3.10.2	Own case study .....	31
3.10.3	Abscesses .....	32
3.10.4	Own case study .....	33
<b>4</b>	<b>Conclusion .....</b>	<b>36</b>
<b>5</b>	<b>Bibliography.....</b>	<b>37</b>





# 1 Introduction

Pet rabbits are becoming very popular in recent years and people are breeding them more. Due to human care, they are living longer, but this has resulted in increased cases of cancer. Thus, the relatively unknown and unexplored field of rabbit oncology is becoming more common. As the number of pet rabbits has increased, so does the number of tumours (Baum, 2021).

Cancer has thus become one of the most common diseases in rabbits. Not only pets are endangered, but wild rabbits also suffer from tumours of a different origin. However, there is more frequency of cancer recorded in pet rabbits (Heatley & Smith, 2004).

Rabbits are most often affected by uterine carcinoma. Haematopoietic tumour lymphoma appears to be the second most common, along with thymoma. Other carcinomas were often recorded on the mammary glands and others, less frequently, on organs such as the adrenal glands and testicles. There are fewer cases of sarcomas and cutaneous tumours, but still more are described in rabbits than other tumours (Kershaw, 2016).

Cancer in rabbits is getting more research attention, but still, in most cases, rabbits do not receive early help. Veterinarians often encounter tumours in rabbits for the first time, and thus cancer is often diagnosed too late, or not at all, and is confused with another disease of benign origin (Bertram et al., 2021).

The owner of the rabbit must always know how to help them as humanely as possible and what the treatment options are. There is a very fine line between whether it is worth treating them or whether euthanasia is the best course of action. Animal welfare is extremely important, and such decisions are always difficult for beloved pets. Just as with any pet in ill health, rabbit owners must consult with knowledgeable veterinarians to make the correct decisions.

Cancer in rabbits often goes undetected due to the lack of symptoms. Rabbit owners should be aware of this issue and thus help their rabbits as early as possible (Kandefter-Gola et al., 2022).

## **2 Aims of the thesis**

The aim of this bachelor thesis is to summarize in detail the current knowledge of oncological diseases in rabbits using recent scientific sources.

## **3 Literature review**

### **3.1 Introduction to cancer**

Cancer is a multifactorial disease based on genetic changes, and cancer cells arise in the body from normal cells caused by genetic mutations—thus abnormal cell growth occurs.

Cancer cells migrate through the body to other tissues and organs, which is called metastasis, making the disease more insidious (Torpy et al., 2010).

In cancer, genes mutate by mistake, this creates cancer cells that grow, and a malignant tumour is formed. Malignant means that cells grow aggressively, uncontrollably and are capable of metastasizing. In this way, it differs from a benign tumour, which may be the original and first stage of cancer, but when talking about a benign tumour, it does not mean an oncological disease ([www.ncbi.nlm.nih.gov](http://www.ncbi.nlm.nih.gov), 2007).

Cancer can arise from spontaneous mutations, genetic inheritance from parents, or from external factors, such as injuries, viral infections, or other diseases (Imran et al., 2017). A substance from the external environment that is responsible for the development of cancer is called a carcinogen (Barnes et al., 2018).

Cancer cells can evade the immune system, thus, the treatment of it and cancerous tumours tend to reappear over time (Spurrell & Lockley, 2014).

Cancer appears to be a very common disease in rabbits and the prevalence is up to 50% after reaching the age of six years (Bertram et al., 2021).

### **3.2 Cancer genetics**

Cancer is based on genetic mutations: irreversible changes of genetic information. Mutations occur in individual genes and can be spontaneous, hereditary, or influenced by external factors (Zingde, 1993).

#### **3.2.1 Basics**

Each cell in the mammalian body has DNA, a carrier of genetic information consisting of thousands of genes. Some genes code for specific proteins that are essential for the organism. All the genetic information in a specific organism is called a genome. Each gene has two alleles, specific forms of a gene; one allele is inherited from the mother and the other from the father (Brooker, 2022).

Mutations are any changes in DNA that usually have a neutral impact on the organism. Heritable mutations are always germline mutations ([www.cancer.org](http://www.cancer.org), 2023).

If only one gene in a cell is damaged, cancer may occur. When a mutation causes damage of a specific gene and mitosis (cell duplication) starts dividing this cell, it leads to genome breakdown. This means that the DNA replication is not controlled (Alberts et al., 2002).

For the proper function of the cellular division (cell cycle), specific genes are needed. Two types of these genes exist, proto-oncogenes, and tumour suppressor genes (Vermeulen et al., 2003).

Proto-oncogenes and tumour suppressor genes are very important genes in mammalian cells. These two types of genes work together and execute normal and necessary functions (Wang et al., 2019). Mutations in the body happen often and these genes intervene and prevent to develop cancer. Problems arise when mutation occurs in one of these specific genes. After mutation, they are no longer able to prevent cancer, thus, increased mutations follow. With age, the ability to repair cells decreases, therefore, cancer is often common at an advanced age (Brooker, 2022).

### **3.2.2 Proto-oncogenes**

Proto-oncogenes are “checkpoints” in cells. They control normal cellular function through cell division, and proper cell growth. Proto-oncogenes control all cells in the body and make sure there are no mistakes in cellular growth and through differentiation (Chin & Gray, 2008). When a mutation occurs in one allele of a proto-oncogene, the whole gene starts to be overexpressed and becomes an oncogene, thus, the cells grow faster and faster. The cell cycle of the proto-oncogene is not turned off, and proliferation (rapid multiplication) is no longer controlled. This overexpression is called GOF – gain of function. Proto-oncogene gains its function and becomes an oncogene (Christopher et al., 1993).

The most common and the first discovered proto-oncogene in all mammals is Ras gene. It is interesting to mention that Ras genes are found not only in all mammals, but in all eukaryotic organisms (Fernández-Medarde et al., 2021). This gene was discovered through a retrovirus causing cancer in rats by impairing the proto-oncogene, therefore named Ras – rat sarcoma virus (Cox & Der, 2010). Ras genes ensure that the cells enter the cell cycle safely and without any damage (Prior et al., 2012). All mammals have three Ras genes, but not all of them cause cancer, some may only be involved in the development of cancer, not its origin. Ras genes are homologs - they are similarly present in several (or all) animal species. This means that organisms carrying this gene share a common ancestor (Karnoub & Weinberg, 2008). Mutations in the Ras gene are in most cases a somatic mutation, meaning that the mutation is not inherited from the parents and cannot be passed on to the offspring. Ras gene mutations are allegedly responsible for deadlier cancers with poorer prognosis (Fernández-Medarde & Santos, 2011).

### **3.2.3 Tumour suppressor genes**

The purpose of proto-oncogenes and tumour suppressor genes is the same - regulation of proliferation, but with the difference that proto-oncogenes stimulate proliferation and tumour suppressor genes inhibit it. Tumour suppressor genes prevent the proliferation of cancer cells or as the name suggests, suppress the tumour. If there is any issue, they can turn off the cell and the cell division does not continue. They can arrest the cell cycle before the DNA is repaired (Imran et al., 2017).

Mutations in these genes cause LOF – loss of function. Tumour suppressor genes lose function and are unable to prevent proliferation, so the multiplication is uncontrolled (Christopher et al., 1993).

Hereditary cancer is more often caused by tumour suppressor genes than proto-oncogenes (Hodgson, 2008). A mammal can inherit one LOF allele, meaning it was already born with one non-functional allele. Then, if the second allele of the same gene loses the function in life, cancer develops (Alberts et al., 2002). Of course, there is an option that a mammal is born with two functional alleles which later stop functioning. This is called the “two hit model”, founded by Alfred Knudson. If the first non-functioning allele is inherited, it has one hit allele, and the mutation is caused in germline cells. This means that the mutation takes place in the germ cells. The mutation in the second allele is always in a somatic cell (Chau & Wang, 2003). Hereditary mutations only happen in germ cells, and contrastingly, the somatic cells only mutate during life (Zingde, 1993). If no mutation is inherited and both alleles are hit during life, the mutation is caused only in the somatic cells, with two hits (Knudson, 2003). This can also be called a sporadic mutation, meaning that there was no inheritance from the parents. The opposite would be called a familial mutation, which means that one allele with LOF has been inherited (Van Der Groep et al., 2006).

It can be deduced that if the tumour develops at a young age in the individual, it is more likely hereditary, because it usually takes several years to mutate both alleles of the same gene (Hodgson, 2008). It is important to mention that an individual cannot be born with both non-functional alleles of one gene, that would already be embryonic lethal (Brooker, 2022).

There is one important difference between these two types of genes. In proto-oncogenes, only one allele can gain function and cause cancer. In tumour suppressor genes, both alleles must lose their functions to develop cancer (Imran et al., 2017).

Some genes act in both ways, so they have both functions – as a proto-oncogene and as a tumour suppressor gene (Wang et al., 2019).

The first tumour suppressor gene found was Rb gene (causing retinoblastoma cancer). This gene occurs in young humans at a very early age of up to four years. The Rb gene is located on chromosome 13 and in normal function suppresses the proliferation of cancer cells (Cruz-Gálvez et al., 2022).

The second tumour suppressor gene found is the most important p53 gene. Almost half of all cancers are caused by mutation in this gene (Ozaki & Nakagawara, 2011). The p53 gene is called a pleiotropic master regulator because it is responsible for many more genes and functions. The definition of pleiotropy is when one gene affects multiple traits. The p53 gene controls many proto-oncogenes and suppresses their proliferation or activates more tumour suppressor genes when needed (Carugo et al., 2019).

The p53 gene has three ways of functioning. The first pathway is DNA repair. The p53 interacts with the BRCA gene and functions as an enhancer for repair (Arizti et al., 2000). Second, the p53 gene can stop cell division. The p53 inactivates the Ras proto-oncogene. Therefore, the Ras gene is turned off, proliferation is suspended and thus there is more time for DNA repair. Unlike the first pathway, here p53 acts as a silencer (Chen, 2016). The third option is apoptosis (Joyce et al., 2023). Apoptosis is programmed cell death. This function does not lead to DNA repair, but the entire cell is immediately destroyed. A damaged cell that needs to be destroyed begins to shrink and DNA degrades. This destroyed cell is then phagocytosed by cells of the immune system (Elmore, 2007).

It is worth noting that BRCA is the most common suppressor gene responsible for hereditary mammary gland cancer (breast cancer in humans) (Kozlov, 2022).

### 3.2.4 Peto's paradox

Rabbits are small animals with fewer cells than large mammals. It would seem then, their probability of developing cancer should therefore be lower. The opposite is true, and rabbits are relatively common oncology patients. This can be explained by Peto's paradox (Compton et al., 2023). The size of the animals and the number of their cells do not affect the probability of cancer. It is more dependent on extra copies of the specific genes. These copies are called paralogues. Paralogous genes are duplicated genes in the same species (as opposed to homologs, which are the same genes in different species) (Jensen, 2001). This can be used with the p53 gene example. For example, an elephant has many paralogs of p53 gene. This means that elephant cells cannot develop cancer in their body (Caulin & Maley, 2011). If one of the p53 genes is damaged, the other paralog is activated. Therefore, for example, an elephant, or other large mammals such as whales, will never get cancer in their lives. Unfortunately, this is not the case with rabbits ([www.medscape.com](http://www.medscape.com), 2015).

### 3.2.5 Mutations

As tumour suppressor genes are caused by loss of function and proto-oncogenes by gain of function, the mutations are different. The best known are point mutations, which can have both proto-oncogenes and tumour suppressor genes (Zhao et al., 2024).

A mutation of one proto-oncogene or a tumour suppressor gene may not immediately lead to cancer. These two types of genes go hand in hand, as with the already mentioned gene p53 which controls many other genes. It may happen that the mutation of the tumour suppressor gene has no effect until the proto-oncogene breaks down, and thus the mutated tumour suppressor gene cannot suppress the growth of the proto-oncogene into an oncogene (Anderson et al., 1992). On the other hand, the tumour suppressor gene Rb is caused only by mutation in this single gene. However, this is not that frequent (Chin & Gray, 2008). Even though the retinoblastoma cancer is caused by the mutation in Rb itself, this gene is still in charge of the E2F proto-oncogene, which, if Rb mutates, is not controlled in any way. This still means that the mutation occurred in the Rb gene, not the E2F gene. The E2F gene just proliferates uncontrollably (Zingde, 1993).

On the contrary, this is the case with colon cancer, where the mutation starts with the tumour suppressor gene APC, which, however, causes only a benign polyp (Hodgson, 2008). After several stages, which can last many years, mutations in the p53, DDC gene and the activation of the Ras proto-oncogene are gradually added. Only then is a malignant tumour developed (Armaghany et al., 2012).

#### 3.2.5.1 Types of mutations in proto-oncogenes

Only one GOF allele is needed to alter proto-oncogene into oncogene (Alberts et al., 2002). In proto-oncogenes, in addition to the regular genetic mutation, there is also a mutation caused by a virus (Imran et al., 2017).

#### 3.2.5.1.1 Missense mutation

Missense mutation, also called nonsynonymous, is one of the point mutations. In many cases, the mutation is neutral and has no effect on the coding protein. Point mutation means that the change occurs in only one nucleotide in DNA. Especially, in missense mutation, the change of a nucleotide changes a single amino acid because of translation (the process where proteins are synthesized). Missense mutation is typical for Ras proto-oncogenes (Hobbs et al., 2016).

Ras proto-oncogenes belong to the group of G proteins, which means that they can bind GTP. GTP (guanosine triphosphate) is an active form of the energy source for cellular activity bound to the Ras genes. Under normal circumstances, GTP alternates with inactive form GDP (guanosine diphosphate), which is the natural state of the Ras gene because with GTP, the cell is activated to divide (McCormick, 1991). In the case of a point mutation, the overexpression of Ras gene is caused precisely by the fact that GTP is not converted back to GDP, and cell division is thus constantly underway, and the cell continues to divide without quitting. GDP is not bound and thus there is no way to stop cell division. A Ras proto-oncogene is overexpressed and becomes an oncogene (Anderson et al., 1992).

#### 3.2.5.1.2 Gene amplification

Gene amplification is a mutation where the number of specific protooncogene is increased, so it logically causes increasing of the encoded protein (a protein that is encoded by the specific proto-oncogene). It is a duplication of the gene (Schwab, 1999).

Mutation causes DNA breakdown and thus the number of copies is increased. Cancer caused by amplification is usually characterized by a poor response to therapy and more serious prognosis (Albertson, 2006).

The mutation is also a sporadic event, not hereditary. As already mentioned above, the type of Ras gene that is not exactly involved in the formation of a tumour can contribute to its growth by means of amplification (Bagci & Kurtgöz, 2015).

#### 3.2.5.1.3 Chromosomal translocation

Translocation is a mutation at the chromosomal level. This can happen during recombination of two non-homologous chromosomes. This mutation was found on the Philadelphia chromosome and most commonly causes haematopoietic cancer such as lymphoma and leukaemia (Zingde, 1993). There is chromosome 9 which carries ABL proto-oncogene and chromosome 22 which carries BCR gene. When these chromosomes are broken, their parts are recombined with each other and chromosome 22 receives ABL gene from chromosome 9. Then chromosome 22 carries both genes, ABL and BCR. BCR gene is not a proto-oncogene, but after their recombination, BCR gene works as an enhancer for ABL, so then ABL is overexpressed. A Philadelphia chromosome translocation is never caused by inheritance (Nambiar et al., 2008).

#### 3.2.5.1.4 Viral integration

During infection with a viral disease, the virus can insert itself into a cell with a proto-oncogene and the mutated cell begins to form a tumour. The virus in this case acts as an enhancer for the proto-oncogene. If the virus binds to the coding proto-oncogene, overexpression into an oncogene will begin (Varmus, 2009). In rabbits, for example, it is caused by papillomaviruses (in humans as well) (Cladel et al., 2022).

Cancer caused by viruses always has two possible pathways, genetic mutation, or epigenetic mutation (modification), which will be explained in the chapter 3.2.5.3 (Ewald & Swain Ewald, 2019).

#### 3.2.5.2 Types of mutations in tumour suppressor genes

Both copies of the gene (both alleles) must be dysfunctional for cancer to develop. If only one copy is damaged, the other copy is sufficient to control cellular processes (Chau & Wang, 2003).

##### 3.2.5.2.1 Point mutations

Nonsense mutation is a type of point mutation that most often occurs in tumour suppressor genes. However, even missense mutation, which was explained in the previous chapter, can occur in tumour suppressor genes.

Transcription is a process when DNA is transcribed into RNA molecule. Codon is a DNA sequence of three nucleotides (substances composed of a nuclear base). STOP codon is the last sequence by which protein synthesis ends (Mordstein et al., 2021). Nonsense mutation is when STOP codon comes earlier than it should have during the transcription, and the final amino acid is also changed. Translation ends before it should (Brown, 2002).

Missense mutations appear to be most common in tumour suppressor genes as well. Missense mutation is also the only mutation that is common to both LOF and GOF (Kato et al., 2003).

##### 3.2.5.2.2 Aneuploidy

Aneuploidy is an abnormal number of chromosomes and is common in cancer. Each species has its own set number of chromosomes. The number of chromosomes is always even because half are inherited from each parent (Orr et al., 2015). A rabbit has 44 chromosomes (Korstanje et al., 1999). Chromosome aberration occurs during cell division and in cancer this means the loss of a chromosome that carries tumour suppressor genes (Sansregret & Swanton, 2017).



### 3.2.5.3 Epigenetics

All of the above-mentioned mutations are at the genetic level, and among them lies less-explored epigenetics at the chromatin level. Chromatin is a complex of DNA wrapped around proteins called histones. Epigenetics is not about DNA sequences and genes themselves, but about the entire complex of genes contained in DNA together with histones (Moosavi & Ardekani, 2016).

Chromatin can be present in two stages – heterochromatin or euchromatin. In the case of heterochromatin, DNA is wrapped around histones very tightly. It also means that no active processes such as transcription take place in it and chromatin is “closed” (Weinhold, 2006). Otherwise, in euchromatin, chromatin is open, active, and gene coding takes place here. Simply stated, heterochromatin is in the "on" phase and euchromatin in the "off" phase. A process called methylation (the methyl group is inserted into the molecule) closes the chromatin into a heterochromatin state, and demethylation (the methyl group is removed from the molecule) opens the chromatin (Tamaru, 2010).

Epigenetics can affect gene activity and the problem arises when the opposite state of chromatin happens. In the case of proto-oncogenes, if demethylation occurs, the chromatin opens up, thereby gaining function, and the principle is then the same - proto-oncogene gains its function and turns into an oncogene. The opposite is true with the methylation in tumour suppressor genes. Chromatin closes and the gene loses its function. Demethylation causes gain-of-function and methylation loss-of-function (Sharma et al., 2010).

DNA methylation is common for tumour suppressor genes and can also be hereditary. During methylation, chromatin is modified, and then causes a mutation such as a point mutation in tumour suppressor genes (Wajed et al., 2001).

In epigenetics, it is most common for the mutation to be caused by an environmental agent such as, for example, cigarette smoking in humans. In the case of rabbits, there is a possible effect of UV radiation, but the cancer is most likely affected by mutation in single specific gene caused by the mutations mentioned above. However, epigenetic mutation can sometimes occur without the influence of the external environment, in short, a random mutation occurs in the genes that encode proteins for chromatin modification (Pogribny & Rusyn, 2013).

There is a huge family of Hox genes that are neither tumour suppressor genes nor proto-oncogenes. Their transcription occurs only during ontogenetic development, and they are methylated before birth and remain switched off throughout the individual's life. If they are accidentally demethylated during life, it can also cause cancer (Li et al., 2019).

## 3.3 Cancer immunology

### 3.3.1 Cancer stages

Everything starts with one single damaged cell that begins to divide. Sometimes only a benign tumour can be the first stage. Any new and abnormal cell growth, whether benign or malignant, is the definition of a neoplasia - neoplastic cells (Srivastava & Grizzle, 2010). A benign tumour is not invasive and, therefore, still “safe”. This is not called cancer yet. If a

benign tumour is suspected, it is best to remove it to prevent the development of cancer. When a benign tumour starts to grow, it is called a precancerous change. A benign tumour turns into a malignant tumour and attacks healthy surrounding tissues and becomes invasive (Brierley et al., 2016).

In most cases, however, a directly malignant tumour is found without precancerous changes and benign form. A malignant tumour initially grows but does not spread. During this time, there is a high chance to undergo treatments such as surgery, radiation, or chemotherapy (Seyfried & Huysentruyt, 2013).

Metastasis is the last and most serious stage. It comes when the malignant tumour is not removed or is removed too late. Cancer cells travel through the lymphatic and blood system throughout the body, invade other organs and cause secondary tumours (Piña-Sánchez et al., 2021). The most common organs for metastases in rabbits are lungs, liver, and lymph nodes, followed by spleen, mammary glands, brain, and bones (Vennen & Mitchell, 2009).

Malignancy can also cause more mutations, and this could lead to resistance to chemotherapy (Wang et al., 2016).

These three stages (benign tumour, malignant tumour, and metastasis) are not strictly given in every type of cancer. There can be more benign stages or only malignant stages. Moreover, not all malignant cells must definitively migrate throughout the body ([www.cancerresearchuk.org](http://www.cancerresearchuk.org), 2023).

It is also not a rule that benign tumours eventually turn into malignant tumour one day. Many benign tumours remain benign (Wang et al., 2016). However, in rabbits, benign tumours can be a major problem as well, particularly when they become large. When the size of the benign tumour grows too large, it can be dangerous for a small rabbit's body. Organs or tracts can be compressed. However, this is not considered an oncological issue ([www.crossriggsvets.co.uk](http://www.crossriggsvets.co.uk), 2023).

### **3.3.2 Types of cancer**

Cancer may develop from different types of cells and tissue. Before becoming metastatic, there is always one original tissue or organ, where the tumour forms.

The most common type is carcinoma. This tumour is developed from epithelial cells. Most organs in a body are made up of epithelial tissue. Adenocarcinoma is a common type of carcinoma which originates from glands (Mullangi & Lekkala, 2023).

Sarcoma originates in connective tissue, such as bones, muscles, tendons, and cartilage. Osteosarcoma is the sarcoma found in bone and liposarcoma appears in soft tissues, most often fat cells (Wright et al., 2023).

Leukaemia is cancer of immature leukocytes – white blood cells, and it arises in the bone marrow. Leukaemia does not form into a mass or tumour.

Lymphoma is also caused by immature leukocytes, but occurs in lymphoid tissue such as thymus, lymph nodes and spleen (Guillerman et al., 2011).

Myeloma is type of cancer located in plasma cells – also lymphocytes, but they are differentiated for producing antibodies ([www.training.seer.cancer.gov](http://www.training.seer.cancer.gov), 2023).

### **3.3.3 Immune system function**

The immune system consists of specific cells and organs of mammalian organisms. The main function is to protect the body from external invaders, which can be any pathogen such as viruses, bacteria, and parasites (Parham, 2014).

When a pathogen appears, the innate immunity attack at first. This is non-specific immunity with a very fast response. Innate immunity involves many different types of leukocytes (white cells) – monocytes, granulocytes, and natural killers (NK). NK cells are the only cells of innate immunity whose precursors are lymphocytes, which is the main type of leukocytes. Their work is clear – kill the pathogen in the fastest way possible (Alberts et al., 2002).

When the innate immunity fails, the adaptive immunity is needed. Cells of innate immunity are required for activation of cells of adaptive immunity. Adaptive immunity is called a specific immunity and includes T and B lymphocytes. Dendritic cells, very important cells of monocytes, are able to present the antigen of foreign cells and thereby activate T lymphocytes. Antigens are molecules of invasive cells that cause an immune response. Then T lymphocytes stimulate B lymphocytes to produce specific antibodies (Parham, 2014). Memory B cells, a type of differentiated B lymphocytes, have an immune memory, and upon repeated encounters with the same antigen, they can differentiate into plasma cells and produce specific antibodies (Largeot et al., 2019).

### **3.3.4 Immunological response to cancer**

Despite the fact that tumour cells come from the same tissue and cells where they originated, the organism is able to recognize them and reacts to them as foreign cells (Kawakami, 2016).

Cells of innate immunity recognize the tumour, attack cancer cells, and eliminate them in many ways such as phagocytes (cell engulfs a “foreign” invader) or by releasing cytotoxins (release of a toxic substance). Cells of innate immunity recognize the tumour and attack cancer cells. The immune response to the tumour is called infiltration. Dendritic cells carry information about the antigen and present it to T cells. Infiltration by innate immune cells is essential before T cell activation (Spranger, 2016). Sometimes B lymphocytes can recognize tumour antigens and thus produce antibodies. It is not completely known why the tumour is sometimes recognized and sometimes not, but it is known that the prognosis of tumours is better when the antigen is recognized (Largeot et al., 2019). T cells are activated through specific Tumour-associated antigens (TAAs) and B cells start producing specific antibodies. The infiltration starts again, T lymphocytes enter the tumour and begin fighting the tumour cells. The specific immunity is activated, and all immune cells fight the tumour at that time. This all can be called an anti-tumour immune response (Vallentin et al., 2015).

Inflammation is always present as a response to a growing tumour, which can contribute to the better development of cancer (Gonzalez et al., 2018).

The tumour may stay under control for a while, but tumour cells grow quickly, and they are able to change genetically over time, so they can easily bypass the immune system (Beer, 2019). For example, tumour cells can lose MHC molecule, which is needed to bind an antigen and thus present it to T cells. Immune cells can no longer detect tumour cells nor distinguish them from normal cells (Palucka & Coussens, 2016). Immune cells can even be inactivated by tumour cells (Spurrell & Lockley, 2014); for example, tumour cells can inactivate dendritic cells, so there is no signal for activation of T cells (Pardoll, 2015). It was also found that innate immunity is reduced when the p53 gene is mutated (Spranger, 2016). Another pathway may be that innate immune cells such as macrophages or neutrophils begin to promote tumour progression. B lymphocytes can also promote tumour growth and, on the contrary, suppress the immune response, causing the immune system to collapse (Largeot et al., 2019).

Until this happens, the process does not show any symptoms. By this time, the cancer is developed, and symptoms may appear. Tumour cells become invasive and malignant cancer cells (Hori & Gambhir, 2011).

There are many limiting factors for a proper immune system response to a tumour. It also depends on the immunogenicity (ability of immune response) and variable immune system between individuals. Naturally, each type of cancer affects the body differently (Disis, 2010).

### **3.4 Predisposition**

Predispositions in rabbits are not always known. It is most likely due to heredity and spontaneous mutation, and the environment does not often play such a strong role in the development of cancer (Tinkey et al., 2012). However, lifestyle (e.g., obesity) and the overall lack of welfare in rabbits can affect some cases or at least contribute to cancerous growths (Rioja-Lang et al., 2019).

Different types of breeds may play a role in predisposition as well (Kershaw, 2016). For example, adenocarcinoma of the uterus is said to be common in the Dutch breed (van Zeeland, 2017), and adenocarcinoma of the mammary gland in Belgian breed (Tinkey et al., 2012).

Other predispositions are age and sex. Except lymphomas, tumours are usually more common in older rabbits (Bertram et al., 2021). After four years of life the chance of tumour occurrence increases significantly (Fox et al., 1971). For tumours of the reproductive system, both sexes can develop different types of cancer. Since uterine carcinoma is among the most common cancers in rabbits, females are more likely to be cancer patients — leaving the rabbit unneutered creates a significantly larger risk of cancer (van Zeeland, 2017). Paradoxically, neutered rabbits are more predisposed to developing thymoma (Bertram et al., 2021).

As already mentioned earlier, viruses can also have a major influence on the development of cancer. One of the most known is a group of papillomaviruses (Tinkey et al., 2012). Cancer caused by papillomavirus is not determined by age but by when an individual becomes infected. Usually, cancer can develop a year or more after infection (Cladel et al., 2019). The infection

occurs through insect bites and is then transmitted by direct contact between rabbits (van Zeeland, 2017). Papillomavirus originates from wild rabbits and then it can also easily spread by direct contact to domestic rabbits (Shope & Hurst, 1933).

In wild rabbits, the papillomavirus causes more benign tumours, and in domestic rabbits it is more common for malignant tumours, with a tendency to metastasize, to occur (Cladel et al., 2019).

As in humans, the papillomavirus causes warts in rabbits, however, they resemble horns and can appear all over the body. This rabbit virus is called Shope Papilloma Virus after Richard Edwin Shope who discovered it, or Cottontail Rabbit Papilloma Virus, because warts were found on cottontail rabbits (Shope & Hurst, 1933). Shope Papilloma Virus causes squamous cell carcinomas, which is a type of skin cancer formed from squamous epithelium (Brabb & Di Giacomo, 2012). The occurrence is mainly in the United States, where Cottontail rabbits are found (Kreider & Bartlett, 1981).

The second virus that causes neoplasm in rabbits is the Rabbit (Shope) Fibroma Virus, also discovered by Richard Edwin Shope. This virus belongs to the Poxviridae family, which caused smallpox in humans (Cikanek et al., 2017). Shope Fibroma Virus also occurs in wild rabbits on the North American continent, but transmission to domestic rabbits is unusual. The virus is also transmitted by insect bites and causes cutaneous tumours (Kerr, 2020). First, the virus causes benign skin fibromas, which later lead to malignant tumours that metastasize (Von Bomhard et al., 2007).

In general, individuals who are immunodeficient, suffer from chronic inflammation, or the already mentioned infection with a certain type of virus have a higher risk of developing cancer (Palucka & Coussens, 2016).

*Picture 1 Warts causing by papillomavirus on rabbit*



Available from <https://www.sfchronicle.com/opinion/openforum/article/What-HPV-ridden-rabbits-can-teach-us-about-16833717.php>

### 3.5 Clinical symptoms

As prey animals, rabbits barely show pain in their bodies, and seem to live with it easily. Recognizing any disease in pet rabbits by the symptoms is unusual and difficult; therefore, making a diagnosis in the early stages of cancer is almost impossible. Additionally, preventive health check-ups, such as blood tests and ultrasound, are not common. These types of examinations also mean putting the rabbit in more stressful situations, which can further complicate their health. However, checking rabbits at home by palpation of the abdomen, for example, can be helpful for some types of tumours (Vennen & Mitchell, 2009).

Skin cancer has the most visible symptoms, since multiple growths can appear anywhere on the body (McLaughlin et al., 2021).

Universal symptoms such as depression, loss of appetite and weight, and lethargy may occur, but these symptoms are very non-specific to any rabbit illness. Symptoms such as dyspnoea (shortness of breath) and haematuria (blood in urine) may point to a more specific tumour location in the body. In cancer, all these symptoms usually indicate a late stage, so the chances of healing are minimal. For example, dyspnoea can already be a sign of pulmonary metastases. Very few symptoms are present before metastases (van Zeeland, 2017).

### 3.6 Diagnosis

When the tumour is bigger, it may be detected by palpation, but it also means that the cancer is not in an early stage, and therefore possibly too late for undergoing a treatment. An enlarged lymph node can also signal cancer. Blood tests, especially to diagnose leukaemia or lymphoma can be helpful, but the results may not show the exact condition of the body such as organ function and, for example, an elevated leukocyte count can indicate any kind of inflammation in the body, not only cancer (Huston et al., 2012).

Radiography (X-ray) and ultrasonography are the first and most common techniques to approach tumour diagnosis. It can already show metastases, most often in the lungs. Because of the air in the lungs, radiography can clearly show metastases; however, it is not effective in other organs. Sonography is more specific for the diagnosis of other metastases, for example, in the liver (Vennen & Mitchell, 2009). Nevertheless, these examinations are not sufficient because the result shows any mass, regardless of whether it is cancer or another benign tumour. Nevertheless, finding metastases indicates that it is most likely a malignant tumour. With these two methods, there is no need to anesthetize the rabbit unless is restless and stressed (King et al., 2012).

Calcification occurs when calcium salts in the body accumulate in organs or tissues. Calcium is always present in the body and is indispensable for cells. In cancer, calcium can be stored in tumour cells that are no longer able to regulate calcium level. This action can occur in some tumours and can easily be seen on radiographic examination (Shou et al., 2022).

CT scan (computed tomography) and MRI (magnetic resonance imaging) are also options and can help diagnose the tumour in more detail (van Zeeland, 2017). However, it is worth considering whether it is beneficial subjecting such a small animal to several demanding

examinations, often putting them under anaesthesia. Another problem with these examinations can be financial inaccessibility (Borkowski & Karas, 1999).

An exploratory laparotomy (abdominal surgery) can also be one of the easiest ways to make an accurate diagnosis, and then, if possible, the tumour can be removed directly (Reusch, 2005).

After finding a tumour in the body, cytologic test should be performed to determine if the tumour is benign or malignant (if sampling is possible depending on which part of the body the tumour occupied in the rabbit). It may be that the tumour tests is negative for malignancy, however, it can also be dangerous for a small rabbit, if a benign tumour grows into large spaces throughout the body (van Zeeland, 2017).

Afterwards, if the results are positive for malignancy, a biopsy would be performed to diagnose the specific type of tumour and where it originates from (van Zeeland, 2017).

Cytological and biopsy examination is harvesting a tissue sample from the tumour and having it examined by a specialist. Often a straight biopsy is done without cytological examination (Millward, 2020).

### **3.7 Treatment**

If the tumour comes from a part of the body that can be removed, a surgical procedure is the first and fastest option for a rabbit (Kershaw, 2016). Removing organ, part of the organ or an amputation of the part of the body such as limb is probably the most effective solution. However, due to their fast metabolism, rabbits are very sensitive to anaesthesia, and mortality during the surgery is quite common. In sick and older rabbits, the risk of danger during anaesthesia is higher. Nevertheless, this is not a rule and sometimes even a young healthy rabbit cannot handle the surgery during a common procedure such as castration (Borkowski & Karas, 1999). There is also a high risk of mortality after surgery, and it often happens that the rabbit survives the anaesthesia but dies after a few days from post-operative complications and poor body condition (Lee et al., 2018).

For tumours which cannot be removed, or metastases already spread through many parts of the body, chemotherapy is a good option. Chemotherapy is medical therapy using chemical substances. However, in rabbits a chemotherapy is not yet so obvious and it is probably non-specific to rabbits but the same as for dogs and cats, so rabbit owners often refuse chemotherapy for this reason. Chemotherapy can have many side effects such as toxicity, anaemia, lethargy, weight loss, and organ inflammation, mostly in the gastrointestinal tract (Huston et al., 2012). However, compared to humans, chemotherapy is given to animals in smaller doses, so side effects are less frequent, but it can also mean that the treatment does not work at all (Lawrence et al., 2015). While in humans chemotherapy is usually injected directly into a vein, in rabbits there is a frequent alternative in the form of a pill, allowing for less stress on the rabbit and fewer veterinary visits. Minimal side effects have been reported in a few cases. However, there are still not enough studies on prognosis or effective chemotherapy for rabbits (Hong et al., 2023).

For some cancers (e.g., lymphoma), radiation therapy is the best alternative, but again with possible side effects (van Zeeland, 2017).

Corticoids can sometimes be added during a treatment such as radiation to reduce inflammation and minimize side effects. If no other treatment is possible, corticoids can slow the growth of the tumour and thus extend the rabbit's life (Palmer et al., 2021).

It is always necessary to consider whether the rabbit's suffering due to these treatments is worth the end result. Special treatments such as chemotherapy for rabbits often require traveling long distances (even to another country), which is stressful for the rabbit and likely not worth it because it requires anaesthetizing the rabbit for each treatment. The treatment also comes at a high price, which unfortunately not every rabbit owner can afford. For such a small and sensitive animal, euthanasia is sometimes the best solution to prevent further suffering of the rabbit (van Zeeland, 2017). In many cases, tumours have been shown to return over time (Huston et al., 2012).

## **3.8 Tumours in rabbits**

### **3.8.1 Uterine adenocarcinoma**

Uterine carcinoma is the most common tumour in female rabbits (and in all rabbits in general). Higher risk increases with age (Walter et al., 2010).

One advantage of this type of cancer is that rabbits can be protected by neutering (van Zeeland, 2017). Rabbits intended for breeding are, of course, neutered after the reproductive period. For the best prevention, neutering should be performed at the age 2 – 3 years. The risk of uterine adenocarcinoma increases rapidly after 3 – 6 years of age. The prevalence can be even up to 75% (Bertram et al., 2021). There is still a probability that tumour appears at a younger age, but that is rather unlikely (Vinci et al., 2010).

Pseudopregnancy in female rabbits may play a role in developing uterine adenocarcinoma. Rabbits act like they are pregnant, but no foetus is present. This condition is common in female rabbits (Chan & Vella, 2013). Pseudopregnancies stimulate sex hormone (oestrogen and progesterone) at a time when these hormones should not be produced in such quantities (Vinci et al., 2010).

Uterine cancer symptoms can be more visible and specific from other tumours. Vaginal discharge and haematuria may be present, but like most cases of cancer in rabbits, there are no symptoms in early stages (Heatley & Smith, 2004).

The diagnosis can be established by ultrasonography, radiography, or laparotomy as the last possibility. Palpation of the enlarged uterus may help as well, since fluid in the uterus may be present (Sommerville, 1998).

The prognosis is quite good, and the most effective treatment is ovariohysterectomy, which is the surgical removal of the uterus and ovaries (Kershaw, 2016). However, if the metastases have already spread, the prognosis is always poor. Uterine adenocarcinoma appears to be one of the most aggressive and rapid malignant tumours for metastatic spread (Bertram et al., 2021). The lungs are the first most commonly affected organ by metastases (Kershaw, 2016).



### 3.8.2 Lymphoma

Malignant lymphoma is the second most frequent type of cancer in rabbits (van Zeeland, 2017). As already stated, lymphoma has the highest prevalence in younger rabbits, most often around 2 – 4 years of age regardless on sex (Bertram et al., 2021). In wild rabbits, it has also been found that lymphomas can be caused by viral integration. Specifically, a virus from the group of herpesviruses has an effect on the stimulation of the lymphatic organs (Hinze, 1971).

Autosomal recessive inheritance can also be a predisposition to the development of lymphoma. This means that two copies of inherited genes on non-sex chromosomes cause the disease to develop (Volopich et al., 2005).

Lymphoma occurs as a mass in the lymph nodes and the lymphatic organs. Nevertheless, it can happen in any organ or part of the body, since lymph nodes are all over the body (Bertram et al., 2021). The most frequent type is multicentric lymphoma, which means lymphoma of the lymph nodes (Huston et al., 2012).

As the appendix is also a lymphatic organ, a lymphoma can appear in it as well but rarely as a primary organ. It is worth noting that the appendix has a much more important digestive function in rabbits than in most mammals, including humans. The liver, spleen, kidneys, and lymph nodes are much more common primary organs for developing lymphoma (Ishikawa et al., 2007). However, the gastrointestinal tract has also been reported as the primary organ since the lymphatic tissue is part of the gastrointestinal tract (van Zeeland, 2017).

When later-stage masses metastasize to more places of the body, it is difficult to diagnose where the primary lymphoma originates (Bertram et al., 2021). Lymphomas spread throughout the lymphatic system. Lymphomas can either be rarely cutaneous and ocular. Ocular lymphoma can very likely be caused after some ocular injury or ocular disease (Keller et al., 2019). Cutaneous lymphomas appear in the form of nodules and can be accompanied by alopecia and crusts (van Zeeland, 2017).

As in humans, B-cell lymphoma is one of the most commonly seen in rabbits (Bertram et al., 2021). Thymic lymphoma, which is less common case, originates from T-cell lymphocytes. Unlike in humans, the thymus in rabbits does not atrophy with age and can even enlarge (Huston et al., 2012). Lymphocytes are usually in the same stage of maturity and not usually completely mature (Gómez et al., 2002).

Symptoms like lethargy and anorexia are not always specific (Robertson et al., 2022), and enlarged palpable nodes may be present (Huston et al., 2012). Only in the eye and cutaneous lymphomas can visible symptoms help in earlier diagnosis (Robertson et al., 2022). Difficulty breathing may be a sign of thymic lymphoma. With thymic lymphoma, chylothorax (chylous occurring in thorax) may be present. Chylous is composed of lymph and fats. Lymph is a normally occurring fluid of the lymph system contained by lymphocytes. Occurrence of lymph in the thorax is a serious condition that is not so common in rabbits, but more in cats and dogs, for example (Pilny & Reavill, 2008).

Blood tests can also show anaemia, radiograph shows the mass, and ultrasonography can help to indicate enlarged lymph nodes. If sonography shows only a mass, a CT scan can help distinguish whether it is lymphoma or a benign tumour (Volopich et al., 2005). A biopsy recognizes a specific type of lymphoma (Robertson et al., 2022).

Cutaneous lymphomas can be surgically removed (Ritter et al., 2012), and other lymphomas can be treated by radiotherapy or chemotherapy (Pilny & Reavill, 2008). Nevertheless, prognosis is in most cases poor (Ishikawa et al., 2007).

### **3.8.3 Thymoma**

Malignant thymoma is an epithelial tumour of thymus, but diagnosis can be easily confused with thymic lymphoma (Pilny & Reavill, 2008). While lymphoma consists only of lymphocytes, thymoma also contains extra epithelial cells. Thymoma is originated from T-cell lymphocytes and lymphocytes are usually mature (van Zeeland, 2017).

Unlike a thymic lymphoma, thymoma occurs more in older rabbits, and neutering may increase the probability of occurrence (Bertram et al., 2021). Another predisposition may be an immune disorder (Tinkey et al., 2012). Thymoma is also more frequent than thymic lymphoma (Huston et al., 2012).

Unlike other cancers, thymomas and lymphomas are more likely to be genetically inherited (Volopich et al., 2005).

Thymoma can metastasize to the organs of the thorax and abdomen, but it is not so common as lymphomas (van Zeeland, 2017).

Symptoms like respiratory problems and diagnosis results by, for example, radiography can be very similar to thymic lymphoma. Samples are needed to be biopsied to differentiate the type of cancer (Bertram et al., 2021).

Another difference is that thymoma can be surgically removed, so the prognosis may be better than in lymphomas (Pilny & Reavill, 2008). Radiation was found as a good therapy for thymomas. However, the chance of side effects is high, and recurrence of the tumour is also likely (Huston et al., 2012).

Very similar and easily confused with thymoma can be thymus carcinoma, which, however, does not originate from lymphocytes, but from the glandular epithelium of the thymus and is less common. Visible symptoms in one reported case were protruding eyeballs (exophthalmos) and fluid in the chest (hydrothorax), and kidney metastases followed (Wagner et al., 2005).

Both tumours, thymoma and thymic carcinoma are classified as tumours of the thymic epithelium (Tartarone et al., 2023).

### **3.8.4 Leukaemia**

Leukaemia is rare in rabbits but can be associated with lymphoma. Leukaemia includes two types, lymphocytic and myelogenous. As in humans, leukaemia in rabbits can be acute or chronic.

Lymphocytic leukaemia (also called lymphoid or lymphoblastic) targets T lymphocytes and myelogenous leukaemia targets myeloid cells, which are also blood cells (not lymphocytes) and originate from bone marrow. Both types can occur in rabbits, with lymphocytic being more common (Moore et al., 2015).

In lymphocytic leukaemia, cancer cells are always present in bone marrow (where they originate) and can be also in lymph nodes or spleen (Huston et al., 2012).

Lymphocytic leukaemia and lymphoma arise from immature T lymphocytes, but leukaemia originates in the bone marrow and lymphoma in the lymph nodes. Another difference is that leukaemia metastasizes through the blood system and lymphoma through the lymphatic system. In the presence of lymphoma, the leukemic phase can occur (Robertson et al., 2022). This means that the malignant lymphocytes of lymphoma arise in the bone marrow and spread in the blood system, just like lymphocytic leukaemia. Therefore, lymphoma can easily be confused with leukaemia as well (Pires et al., 2016).

The cause, symptoms, diagnosis, and treatment of leukaemia are almost exactly the same as lymphoma (Guillerman et al., 2011).

### **3.8.5 Mammary adenocarcinoma**

Mammary carcinomas are also among frequent tumours in female rabbits and adenocarcinoma is the most prevalent. The tumour is most common around four or five years of life and female rabbits must be spayed at an early age to prevent mammary adenocarcinoma (Schöniger et al., 2019). However, it is proven that male can also have mammary adenocarcinoma. Different breeds may play a role (Bertram et al., 2021).

Four pairs of mammary glands arranged in two lines are composed of epithelial cells. Like in the uterus, mammary glands are affected by hormones thus pseudopregnancy may have the same impact for developing mammary adenocarcinoma. Multiparity (multiple offsprings at one birth) and more pregnancies during the life also increase the likelihood of adenocarcinoma. Frequent lactation has an effect on another female hormone prolactin, and it then affects the occurrence of the tumour (Schöniger et al., 2019). Mammary and uterine adenocarcinomas may be then related to each other (Bertram et al., 2021). When mammary adenocarcinoma is found, uterine adenocarcinoma is also often diagnosed, or adenocarcinoma in mammary glands may be a metastasis of the uterine carcinoma (Vennen & Mitchell, 2009). When carcinoma originates in the mammary glands, spreading to other organs is also likely (Summa et al., 2014).

It has been proven that the precursor of mammary adenocarcinoma can often be a benign cystic lesion. Genetic inheritance may play a role for developing adenocarcinoma as well (Schöniger et al., 2019).

The mammary glands are enlarged, and the tumours may be palpable. Discoloration of the teats and a milky discharge may also be present (Tinkey et al., 2012).

Mammary tumours can often be benign lesions, so it is important to perform a cytology, however, as already mentioned, a benign tumour of the mammary gland often turns malignant over time.

Surgical removing of mammary glands is necessary for treatment, and it is the most effective way to avoid metastases. Because of the relation between the mammary glands and the uterus, ovariohysterectomy is recommended. If surgery is not possible or the tumour has already metastasized, hormone therapy slows tumour growth. Radiation or chemotherapy are always an option for a chance of cure (Summa et al., 2014).

### **3.8.6 Testicular malignant tumours**

Testicular tumours are rarer, but interstitial cell tumours are the most common type (Alexandre et al., 2010). Interstitial tumours originate from Leydig cells (testicular cells producing testosterone). Other testicular malignant tumours were reported, such as testicular adenocarcinoma, Sertoli cell tumour or seminoma, which originates from germ cells (Irizarry-Rovira et al., 2008).

Older and unneutered males are the high-risk patients. Cryptorchidism, which is known as undescended testicles at the right age, also increases the risk (Alonso, 2022).

Symptoms can appear as enlarged testicles, which is a visible sign, and the chance of recovery could be higher than most other tumours (Tinkey et al., 2012).

Testicular tumours are easily visible and palpable, ultrasonography may be enough for examination. Treatment is surgical removing (castration). Even if it is a benign mass, the rabbit should undergo the surgery anyway and the examination of the sample can be done afterwards (Alonso, 2022).

The prognosis is relatively good with a high chance of recovery. Another reason for the better prognosis is that testicular tumours do not have such a tendency to metastasize. When it does metastasize, it is most often to the lymph nodes (Banco et al., 2012).

### **3.8.7 Adrenal carcinoma**

Adrenal glands are a pair of glands located above the kidneys that have an important function in the producing specific hormones. Carcinoma of adrenal glands is rare and may occur more as a secondary organ of metastasis (Heatley & Smith, 2004).

Adrenal carcinoma is more common in older neutered rabbits, since the castration leads to higher production of testosterone hormone in adrenal glands, and this promotes the development of carcinoma. Testosterone is a sex hormone that plays an important role in the male reproductive tract, so the occurrence of adrenal cancer is more common in males, but testosterone is present in the female body as well but in small amounts (Baine et al., 2014).

Adrenal cancer may develop aggressive (e.g., attacking and biting people) and sexual behaviour in rabbits. In later stages it may be palpable in the abdomen (Lennox & Chitty, 2006). Metastases are possible (Tinkey et al., 2012).

Sonography and analysis of hormone concentration show the results (Baine et al., 2014). Drug therapy to reduce sex hormones is the best solution. Surgical removal of the adrenal glands is possible too, but it is more complicated due to the placement of the glands in the body and their connection to the veins and other organs. Thus, the rabbit's behaviour is likely to reappear (Lennox & Chitty, 2006).

### **3.8.8 Sarcomas**

As mentioned in chapter 3.3.2., sarcomas are malignant tumours arising from connective tissue cells. Most of sarcomas originate in the musculoskeletal system. They are often locally aggressive or metastasize frequently. It is likely that due to aggressive growth, the sarcoma will

grow into the surrounding tissue. For example, a sarcoma from the surrounding muscle that is around the lungs, will grow over time into the lungs.

According to the distribution of connective tissue, this diverse group is divided into many other tumours (Vodanovich & Choong, 2018). They appear anywhere on the body in the form of various lumps or bumps. In general, the most common sarcomas tend to be from soft connective tissue, such as muscles, fat, vessels and nerves. Predispositions may be infection from the external environment and inflammation, and more males have been noted (Park et al., 2016).

#### 3.8.8.1 Bone sarcomas

Osteosarcoma, a bone sarcoma, may be more frequent than other sarcomas, but it is still rare. No gender or breed predisposition were reported, only a predisposition to older age, as is usually the case (Heatley & Smith, 2004).

Osteosarcoma can appear anywhere on the skeleton, most commonly in the limbs or skull. However, osteosarcomas of the joints or spine have also been reported (Stans, 2023). Osteosarcoma does not tend to metastasize as much as other tumours, but it is more likely to be locally aggressive and grow on its own through the bone. If it metastasizes, then most often to the lungs, and there are often micrometastases that are not caught by the radiograph (Kondo et al., 2007).

Depending on the location, specific symptoms such as lameness or swelling are present (Ishikawa et al., 2012). Sometimes subcutaneous masses occur with or without the presence of osteosarcoma, which is very rare, because they are not connected to any bone. This is called extraskeletal osteosarcoma and it metastasizes more (Wijesundera et al., 2013).

With the help of radiography, a tumour can be easily found on the bones, but it can easily be confused with a benign growth. The radiography also helps with the diagnosis of pulmonary metastases.

Limb amputation is the best and most effective solution, but if it is on the skull, surgery is not possible, and its rapid aggressive growth is fatal. Chemotherapy is helpful if the osteosarcoma grows into the surrounding bones and amputation of this additional part is no longer possible. It can also prevent overlooked metastases. However, it was reported that a rabbit died a few days after amputation because the micrometastases in the lungs were not visible by radiography, so no additional treatment such as chemotherapy was applied (Higgins et al., 2015).

Chondrosarcomas are sarcomas arising from cartilage. Cartilage is an avascular and flexible connective tissue formed from chondrocyte cells. Compared to osteosarcoma, it is much rarer. Chondrosarcoma is mainly found in bones, but exceptionally it can also be found in soft tissue (Gazendam et al., 2023).

Chondrosarcomas can be palpable on the bones and the rabbit is very likely to be lame and in pain, and there is a high probability of lung metastases. Treatment other than surgical removal and amputation has not been reported for chondrosarcomas (Garcez, 2009).

Intraocular chondrosarcoma has been reported as a post-traumatic sarcoma. The rabbit was previously infected with *Encephalitozoon cuniculi*, a parasite that most commonly attacks

the brain. It is most likely believed that this infection was a predisposition to chondrosarcoma (Mikiewicz et al., 2020).

#### 3.8.8.2 Liposarcoma and fibrosarcoma

Liposarcomas and fibromas originate from soft tissue sarcomas. Liposarcomas grow from fat cells and fibrosarcomas are from fibrous connective tissue, therefore from tendons and ligaments (Zafar & Wheeler, 2023).

Both sarcomas have a similar incidence and characteristics, but fibrosarcomas appear to be more common than liposarcomas and are more widely described (Baum, 2021).

They do not tend to metastasize so much as to grow locally into surrounding tissues and organs (Zafar & Wheeler, 2023).

For both liposarcoma and fibrosarcoma, it is possible that the predispositions are various injuries or viral infection (Von Bomhard et al., 2007). There is also speculation as to whether vaccination could have any effect on the development of these types of sarcomas. In some cases, the sarcoma appeared in the same place where the needle was inserted (Petterino et al., 2009).

Fibrosarcomas are recorded mainly in old rabbits after seven years of life (Baum, 2021).

Both sarcomas can occur anywhere on the body, wherever there are tendons, ligaments or adipose tissue. The most often they have been recorded on the limbs and thorax, where there was no other option than palliative treatment. If it is located on a limb, the best solution is again amputation (Von Bomhard et al., 2007).

If they are cutaneous or subcutaneous, they are easily palpable, and the diagnosis can be made in time. Other visible symptoms, including lameness, pain during movements or hair loss at the site of the tumour, can be helpful too (Heatley & Smith, 2004).

Both types of sarcomas have a great predisposition to reappear in the same place and grow to a larger size. If an amputation has already been performed, the patient is more inclined to palliative care (Petterino et al., 2009).

#### 3.8.8.3 Muscle sarcomas

Leiomyosarcoma is a smooth muscle tumour, so it can occur in any organ in the body (Park et al., 2020). Sarcomas have been reported in elderly individuals in the intestine, stomach, and uterus. Since smooth muscle is also contained in the skin, cutaneous leiomyosarcomas have also been reported. Leiomyoma, a benign form, is more common in rabbits, however, leiomyoma has not been reported to be a precursor to leiomyosarcoma (Tinkey et al., 2012).

In uterine leiomyosarcoma, haematuria may be present and thus the tumour may be easily confused with uterine adenocarcinoma. However, an ovariohysterectomy is required anyway (Park et al., 2020). Uterine leiomyosarcoma is the second most common malignant tumour of the uterus (Murakami et al., 2024).

Rhabdomyosarcoma arises from skeletal muscle (myocytes cells) and is less common than leiomyosarcoma. It can occur all over the body and since the muscles are located under

the skin, it is easily palpable. Tumours were noted on both the limb and the abdomen and grew rapidly (Park et al., 2016). Metastases were noted not in the organs, but subcutaneously throughout the body (Von Bomhard et al., 2007).

#### 3.8.8.4 Myxosarcoma

Myxosarcoma originates from fibroblasts and can form anywhere in the connective tissue. Another characteristic of myxosarcoma is that it contains a myxoid matrix. Myxoid means that the tissue has a high content of specific polysaccharides. Fibroblasts are most often found in the skin. A benign form, myxoma, occurs in rabbits in the heart and can eventually become a malignant myxosarcoma. Myxosarcoma most often occurs subcutaneously (Das et al., 2022). Not one of the recorded cases of myxosarcoma was female and this sarcoma appears to be the most sex-specific (Von Bomhard et al., 2007). In rabbits, myxosarcoma is mainly caused by Rabbit Shope Fibroma Virus (chapter 3.4) (van Zeeland, 2017).

#### 3.8.8.5 Hematopoietic sarcoma

Hemangiosarcoma is formed from endothelial cells, which are on the inner surface of blood vessels. It can occur in blood vessels anywhere in the body, so for example in any organ and under the skin. Since the tumour is already in the blood vessels, metastases are highly expected and have been reported in several organs, even in the heart. Most primary hemangiosarcomas have been reported in the liver (Guzman et al., 2000). Hemangiosarcoma in the uterus was recorded, which progresses in exactly the same way as any other uterine neoplasm (Murakami et al., 2024).

Blood clots and internal bleeding can be a symptom; however, these signs can only be proven at autopsy. Chemotherapy is recommended as treatment, but surgical excision, which means removing the tissue, is also possible (Heatley & Smith, 2004).

### 3.8.9 Skin malignant tumours

Melanoma is a very aggressive skin tumour originated from melanocytes, skin cells producing pigment melanin (Liu & Sheikh, 2014). Melanoma in rabbits is most often located on the head, and studies have confirmed that melanomas are more common in males. Melanoma has been reported on the eyelids and scrotum as well. As in humans, this aggressive tumour metastasizes very quickly, most often to the lungs, liver, kidney, spleen, or lymph nodes. It is therefore very important to carry out further examinations to check for organ metastases (Baum, 2021).

Melanoma is easy to notice, as it usually appears as a black growth, eventually with ulcers or necrosis (dead tissue) (Abbate et al., 2023). Melanoma can also be amelanotic. This means that melanoma does not contain pigment and therefore is likely to be overlooked. However, due to the size of the body and animal's hair, amelanotic melanoma is a bigger problem in humans

than in rabbits. When the pigmentation level is low, it can also be easily confused with sarcoma, so a biopsy is needed (Ueda et al., 2018).

Melanoma can also be locally aggressive, which means that it does not necessarily metastasize, but it grows and spreads very quickly in the local place where the melanoma first started (van Zeeland, 2017).

As in humans, the appearance of melanoma can be caused by frequent UV exposure and therefore melanomas occur in rabbits mainly on the head, where there is less hair. The occurrence of melanoma has also been confirmed in wild rabbits (Abbate et al., 2023).

Since melanoma is one of the most aggressive tumours, the prognosis is poor and without overall treatment of metastases with chemotherapy, the chance of survival is small. The advantage, however, is that melanoma is easy to notice, so there is still a chance that the diagnosis would be made early (Liu & Sheikh, 2014).

Squamous cell carcinoma tends to be more locally aggressive, but metastases are also possible. The presence of papillomavirus (chapter 3.4) is often the cause of this type of skin carcinoma. The research also showed that neutered rabbits were more frequent patients, and the age does not matter (McLaughlin et al., 2021). If squamous cell carcinoma metastasizes, it is very common to be spread to lymph nodes and then also to the lungs (Brabb & Di Giacomo, 2012).

It is very common for rabbits to have a skin tumour, but in most cases, it is not a cancer but a benign lesion (Abbate et al., 2023).

Depending on the location of the malignant tumour, surgical removal may be considered. However, due to the high frequency of aggressive growth and metastasis, chemotherapy or radiotherapy is needed. Recurrence of melanoma is also possible. In most cases, skin cancer in rabbits is fatal (Brandão et al., 2015).

### **3.8.10 Other primary neoplasia**

Other organs not yet mentioned are more common for secondary metastases than as a primary origin of a malignant tumour. However, a few cases have been reported.

Renal neoplasia was rarely recorded as renal adenocarcinoma, renal nephroma and urinary bladder leiomyoma (Vennen & Mitchell, 2009). Kidney tumours were more often recorded in laboratory rabbits, so the diagnosis was made postmortem, but the tumour could be recognized by palpation. If only one kidney was affected, it could be operated on. Nevertheless, the prognosis is poor in terms of difficult treatment of a vital organ and the likelihood of metastases (van Zeeland, 2017).

The lungs, being the main and most common organ for metastases, can also be the primary organ with cancer, but very rarely (Vennen & Mitchell, 2009). The symptoms are the same as for the symptoms of metastases, thus dyspnoea and lethargy. Diagnosis and treatment are



therefore also similar, but it is necessary to check other organs for reasons of metastases and to confirm that the tumour originates primarily from the lungs (van Zeeland, 2017).

Rarely, the tumour can also appear in the upper respiratory tract, so the symptom can be, for example, nasal discharge (Baum, 2021).

The liver, as a lymphatic organ, is more often associated with lymphoma than with carcinoma. Bile duct carcinoma has been reported rarely, but the liver itself tends to produce more benign tumours. Hepatic angiosarcoma was noted. Angiosarcoma originates from the wall of blood vessels (Tinkey et al., 2012).

In rabbits, the liver is very well hidden behind other organs, so it can be difficult to see where the tumour is originally growing from. Sonography can help determine if the tumour originates from the liver (van Zeeland, 2017).

Pancreatic adenocarcinoma has also been recorded, which had a very similar course to liver cancer (Bertram et al., 2021).

Carcinomas have also been recorded in the gastrointestinal tract, but again the development of lymphoma in gastrointestinal organs is more common. Adenocarcinoma can arise in stomach or colon. Symptoms may include diarrhoea, loss of appetite and weight (Reusch, 2005).

Brain tumours are most commonly found as neurofibrosarcoma, sarcoma arising from peripheral nerves, or glioblastoma, glial cells in nervous system. Schwannoma (composed of Schwann cells) or ependymoma (formed in fluid-filled spaces) are benign in most cases, but malignancies have rarely been reported. Tumours can also occur in the spinal cord or eyes (Baum, 2021).

Symptoms are more specific and include seizures or paralysis. Surgery is not possible due to the location and radiation therapy is usually unsuccessful (van Zeeland, 2017).

## **3.9 Oncological case studies**

### **3.9.1 Mammary carcinomas**

Rex female rabbit Paris, a purebred with good lifestyle and physical condition. Paris was pregnant once, at the age of 1.5. Three years after pregnancy (after the fourth year), the owner found fluid in the mammary gland and took Paris immediately to a veterinarian. She was examined by a sonograph. An enlarged uterus was detected, but no signals of a tumour or cancerous changes. On the same day, Paris underwent an ovariohysterectomy for future prevention.

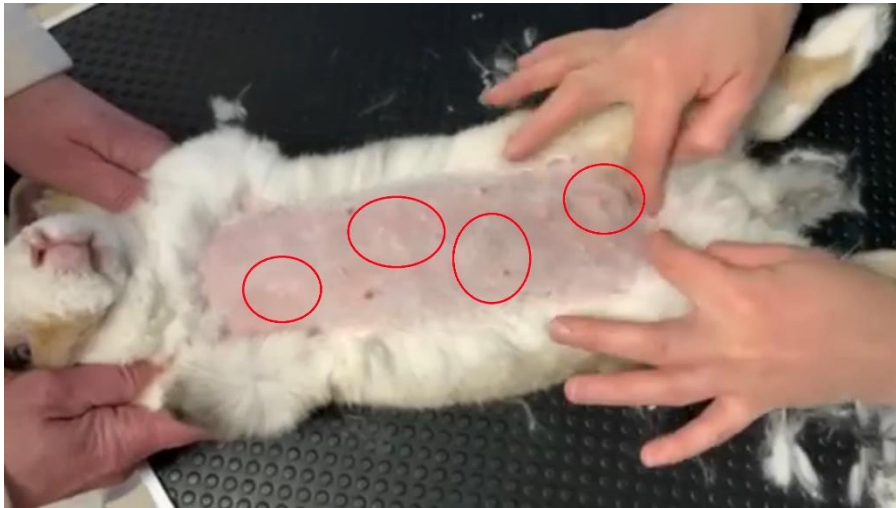At the age of 6.5, the owner found a small tumour on one mammary gland. A biopsy was performed, and the result came back as carcinoma. As Paris was already in old age, the veterinarian did not recommend any treatment for cancer, and when surgery was considered, the tumour had spread throughout the mammary glands, so

the complete removal was not even possible and the chances of a rabbit surviving such a difficult operation at that age are risky (Lee et al., 2018).

Paris got supportive treatment such as immune supports and antibiotics. She began to lose her appetite and weight and became more apathetic. She was almost seven years old. Paris lived another year with worsening conditions. The tumours later began to enlarge and bleed, as seen in the *Picture 3*. Paris died at the age of eight by euthanasia as a decision of the owner, because her life started to be painful and unpleasant for her.

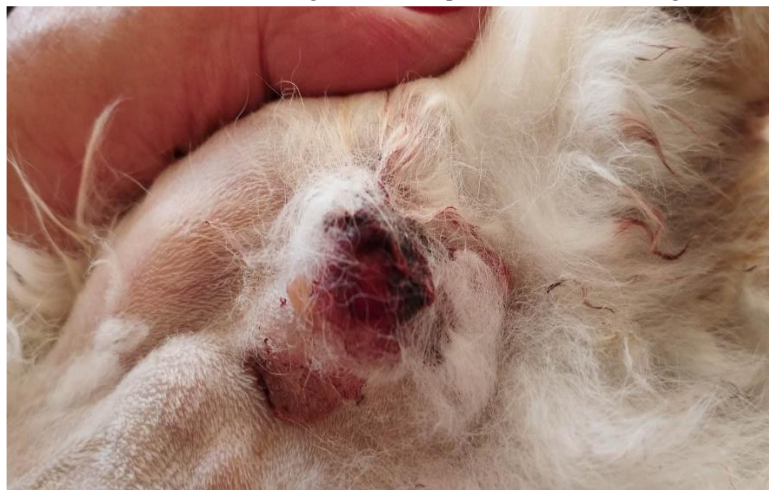There may be a link between an enlarged uterus and mammary carcinoma. It is very likely that her pregnancy and late hysterectomy led to an increased risk of developing a tumour caused by sex hormones. An enlarged uterus can be uterine hyperplasia, which means that there is an increased production of cells, and this condition is also affected by hormones and mammary gland carcinoma is also associated with it (Degner et al., 2018).

*Picture 2 Examination of Paris with less visible tumours of the mammary glands, Prague, on February 16, 2023*



*Source: Barbora Žáčková*

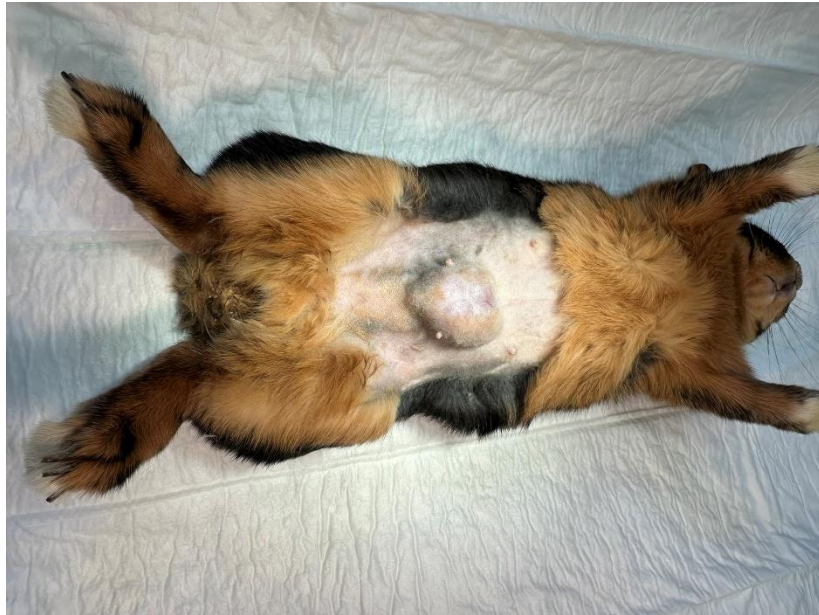*Picture 3 A tumour in an advanced stage when it ruptured and bled, Prague, on May 5, 2023*



*Source: Barbora Žáčková*

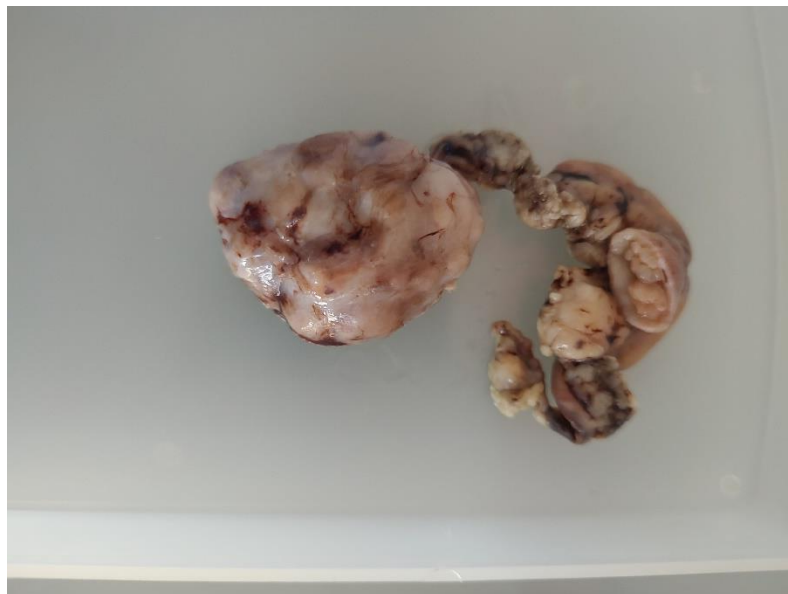A six-year-old female dwarf rabbit was undergoing spaying. During this occasion, the carcinoma on the mammary gland was also removed, which was already quite large, but had not spread over the entire mammary glands like in Paris's case, did not burst, and probably did not cause further damage. The tumour was removed without any problems during spaying and the rabbit continues to live.

*Picture 4 A female rabbit before removal of the mammary carcinoma, Czech University of Life Sciences, 2023*



*Source: Ing. Kateřina Zadinová, Ph.D.*

*Picture 5 Mammary carcinoma successfully removed from female rabbit, Czech University of Life Sciences, 2023*

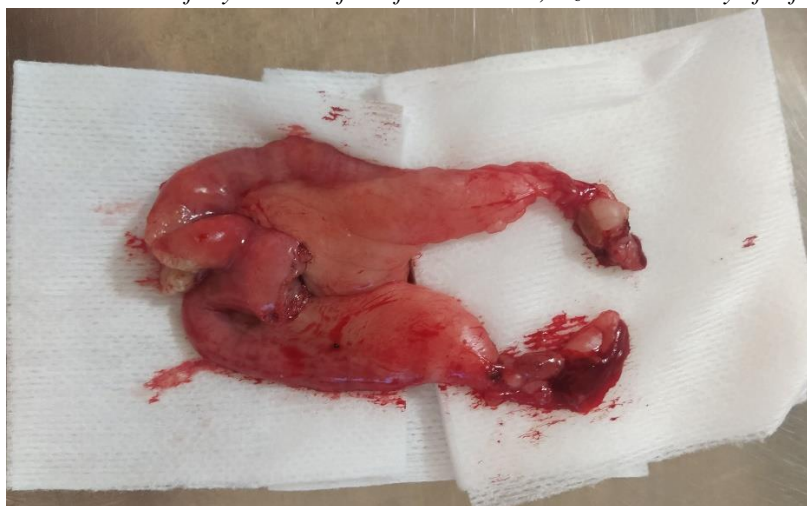

*Source: Ing. Kateřina Zadinová, Ph.D.*

### 3.9.2 Uterine adenocarcinomas

A four-year-old unneutered mix female bred for sudden haematuria arrived urgently at the vet. The enlarged uterus was palpable, and the owner refused further examinations such as blood tests, radiography, or sonography due to the high costs. The rabbit therefore immediately underwent a laparotomy, during which the enlarged uterus with adenocarcinoma was confirmed, and a hysterectomy was subsequently performed immediately.

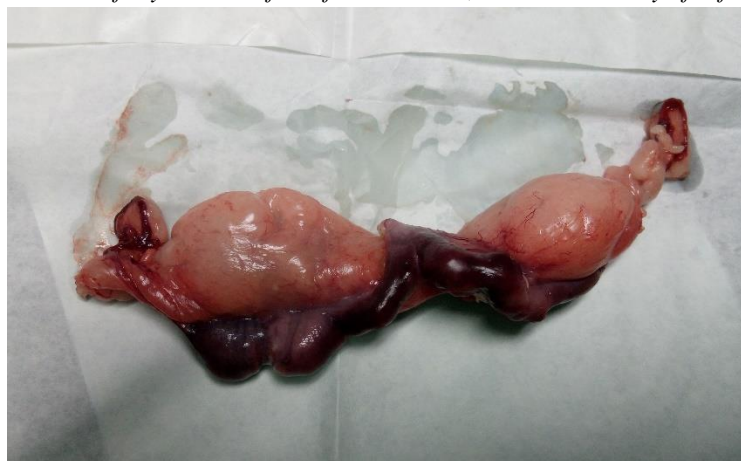*Picture 6 Uterus successfully removed from female rabbit, Czech University of Life Sciences, 2023*



*Source: Own resource*

A three-year-old unneutered female was undergoing a preventive check-up and vaccination. Then, as a precaution and due to the rabbit's age, hysterectomy was performed. During the surgery, an adenocarcinoma of the uterus was found without any of the symptoms the rabbit was showing.

*Picture 7 Uterus successfully removed from female rabbit, Czech University of Life Sciences, 2023*



*Source: Own resource*

Both surgeries of the rabbits took place without complications, even considering their older age. Other complications and metastases with them were not reported.

### 3.9.3 Sarcoma

Borůvka is a male crossbred from the pet shop. At the age of five months, the owner found a tumour on his upper part of the left front limb. The veterinarian diagnosed it as an abscess and put Borůvka on antibiotics. The veterinarian was also sure that this could happen after vaccination, but it is important to point out that the first abscess appeared before Borůvka's first vaccine. A few months later, Borůvka was castrated, so the abscess was immediately surgically removed so that the rabbit would not be exposed to anaesthesia multiple times. The veterinary did not do a cytology. In a month, the abscess appeared again in the same place. Borůvka was treated for an abscess for over a year. Borůvka started to be in pain and the result was not getting better, so Borůvka got sepsis (an infection throughout the body). The owner changed to a different veterinarian.

Another veterinarian diagnosed outright as fibrosarcoma, which is a locally aggressive tumour and tends to reappear (Wright et al., 2023). The veterinarian also did not do a biopsy because he had a lot of experience with fibrosarcoma in rabbits. Around the age of two, Borůvka underwent a surgery in which the tumour with part of the muscle was removed (*Picture 8*). In a few months, the sarcoma reappeared again, so Borůvka's entire front limb was amputated. Within six months, the sarcoma in the amputated part of the muscle began to grow again. This means that the tumour must have already spread into the surrounding tissue. A fourth surgery was required and this time all the muscles, which remained after the amputated limb, were removed. However, the tumour reappeared very quickly and since it was not possible to remove the muscle and only the skin remained, surgery was no longer an option.

Borůvka is now almost four years old. He is in palliative care and only receives pain medication. So far, he is cheerful and seems to be pain free thanks to the medicine. The owner refused chemotherapy due to possible side effects. Nevertheless, in time the owner will see if chemotherapy is reconsidered.

Signs of metastasis are not yet known, but Borůvka has never undergone any further examinations. Since this type of tumour tends to be more locally aggressive, there is a chance that there are no metastases. However, due to the rapid growth of the tumour locally, there are great fears that it will soon grow into the lungs (Yiallourous & Kube, 2010).

It cannot be confirmed that it is indeed a fibrosarcoma, given that the veterinarian never did a biopsy. It could also be another soft tissue sarcoma.



*Picture 8 Borůvka after the first surgery where a part of the muscle was removed, Prague, on July 2, 2022*



*Source: MUDr. Anna Burantová*

*Picture 9 A completely amputated limb after healing, Prague, on March 13, 2023*



*Source: MUDr. Anna Burantová*

### **3.10 Differential diagnosis of tumours**

Many benign lesions are easily confused with cancer. Radiography or sonography usually show any mass, but it cannot be more specific when the tumour is not examined cytologically.

### **3.10.1 Benign tumours**

Benign tumours are also characterized by abnormal cell growth caused by mutations, except that the cells of a benign tumour are not different from the original cells in the body. Benign tumours never metastasize to other tissues and organs and tend to grow slowly (Boutry et al., 2022).

Benign tumours do not receive as much research attention due to their lesser threat, but differences between malignant and benign tumours are allegedly explained by lacking specific genetic mutations during benign tumour formation or a mutation occurs in a gene that does not cause cancer. It is known that benign tumours are generally caused by fewer mutations, and they do not lead to more mutations, as is standard for malignant tumours (Wang et al., 2016).

Lipoma, a benign tumour of fat cells, can grow anywhere in the body. It is mostly under the skin, but it is not ruled out that it can also appear in the body cavity. Lipomas are more common in older rabbits (Millward, 2020).

Lipomas usually grow slowly, but if they grow rapidly, they could compress a part of the rabbit's body and possibly result in a fatality ([www.crossriggsvets.co.uk](http://www.crossriggsvets.co.uk), 2023).

It is important to note that lipomas are not precursors to liposarcomas. There is no chance to develop into cancer. Nothing is ever out of the question, but it is very unlikely (Zafar & Wheeler, 2023).

Treatment is usually not necessary until the location of the lipoma becomes uncomfortable for the rabbit, then, if possible, the tumour can be surgically removed. The only threatening factor is their size ([www.crossriggsvets.co.uk](http://www.crossriggsvets.co.uk), 2023).

It can be the same with a fibroma (it does not mean the Shope fibroma), a benign tumour of fibrous tissues. However, it was recorded in rabbits rather as a fibrolipoma (Baum, 2021).

Adenomas are benign tumours of glandular epithelium. Adenomas have been recorded in rabbits more than lipomas, most often in the mammary glands, adrenal glands, and the bile duct (Bertram et al., 2021). Adenomas are slightly more likely to turn into a malignant tumour over time (Hall, 2015).

Leiomyoma, a benign tumour arising from smooth muscle, has been reported in the uterus and gastrointestinal tract of rabbits.

Haemangioma, a benign tumour of blood vessels, was noted on the ovary (Baum, 2021). It rarely occurred on the lungs, leading to dyspnoea and the rabbit died (Kandfer-Gola et al., 2022).

### **3.10.2 Own case study**

A male crossbred rabbit, Franz Joseph I, developed a lump on his nasal bone at the age of five. At first, the veterinarian suspected overgrowing teeth and examined Franz Joseph I with radiography. An X-ray showed a new growth, so the veterinarian directly said it is an osteosarcoma. The veterinarian did not want to make another examination and just said that it

will grow fast, and the rabbit does not have much time for survival. Surgery was not possible due to the area of placement on the skull. An owner had to ask for a cytology, and the result came back as harmless lipoma. Over time, the lipoma became smaller, and never threatened Franz Joseph's life.

*Picture 10 Franz Josef I with stitches after cytological examination, Prague, on April 13, 2021*



*Source: Own resource*

### **3.10.3 Abscesses**

As mentioned in the case in the chapter 3.9.3., the sarcoma went undiagnosed for almost a year because of the ever-growing abscesses. However, it is not known whether the tumour was simply mistaken for an abscess, or whether the tumour may have caused the abscess.

An abscess is a cavity filled with pus. It is caused by an infection, and in rabbits it is mainly due to the presence of bacteria. Dental abscesses caused by dental infection are common (Reusch, 2005). Skin abscesses are also common in rabbits, but these are very different in appearance from a tumour, therefore interchangeability is unlikely (Millward, 2020).

Dental abscesses are easier to diagnose by radiography so they cannot be confused with cancer as much as mass in the cavity. The wall of the abscess in rabbits is very thick and radiography and sonography are not sufficient at all. A CT scan seems to be more specific for diagnosis, but it is not available in all veterinaries and the cost is also higher (Vennen & Mitchell, 2009).



#### 3.10.4 Own case study

At the age of almost seven years, a large mass appeared in Franz Joseph's abdomen. The veterinarian examined the rabbit by sonography and said that a huge mass was forming from the liver, and it was most likely a malignant tumour.

The owner changed a veterinary, and the new veterinarian took a radiography. It was very likely to be cancer because visible calcification was present in the tumour. The veterinarian wanted to do a cytology directly, but after the needle was inserted, only a cloudy beige fluid came out of the tumour, which is illustrated in *Picture 12*. The veterinarian took 150 millilitres of this fluid, and cytology showed only inflammation but no cancer cells. Such a thick light fluid is not part of a malignant tumour. A cancerous tumour is firm, unbounded and irregular, and can be bloody (Baba & Cătoi, 2007).

It probably was not cancer, but no examination in this case except an exploratory laparotomy would have shown an accurate diagnosis. It was still not known whether there was a smaller tumour somewhere that could cause this rare inflammation.

During the surgery, a large abscess was found arising from the liver, as well as many small abscesses spread over all the organs in the abdominal cavity. Small abscesses spread through the blood system like metastases of malignant tumours, and it indeed looked like cancer (*Picture 14*).

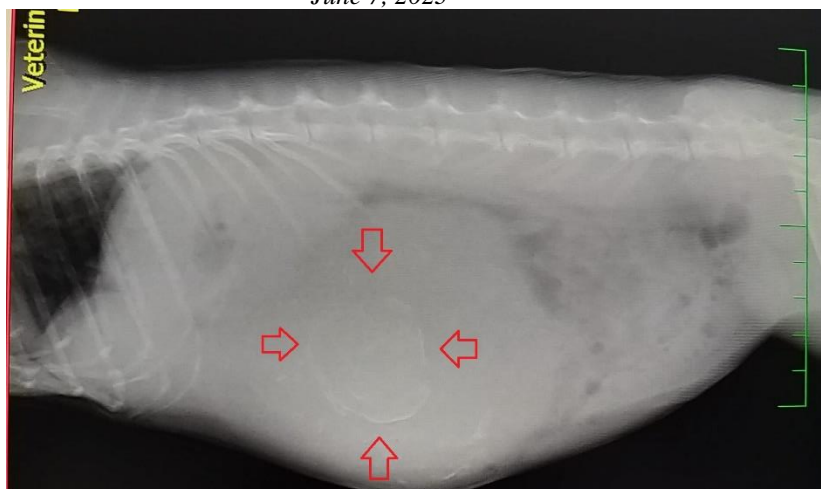
A large abscess emanating from the liver, noted in the *Picture 13*, was removed from the body. Franz Josef did not survive the surgery, due to the number of abscesses all over his body and thus inflammation in the entire abdominal cavity and peritonitis. Franz Josef never showed the slightest symptoms. Apart from a palpable abscess, he was very active until the last moment.

After examining the abscess, no signs of cancerous origin were found. The abscess was hollow inside and filled with pus.

The diagnosis took almost three months before finding a veterinarian who had previous experience with it and knew how to proceed, and until the last moment it was not known whether it was cancer or not.

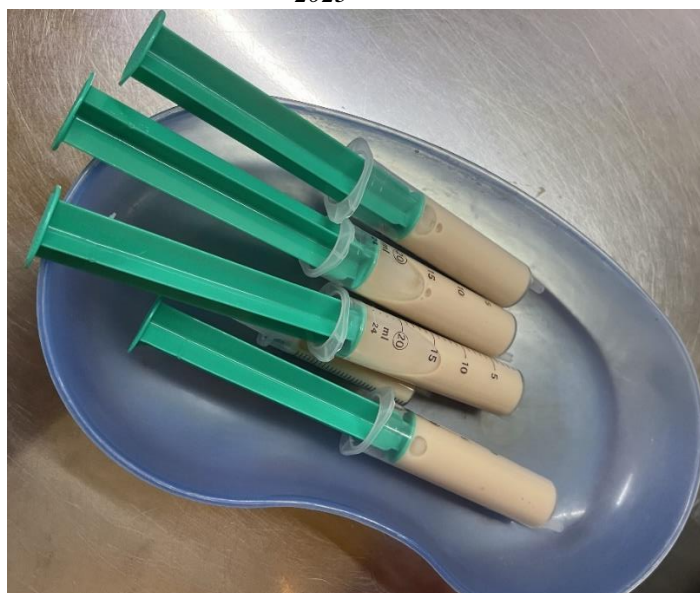Abscesses in rabbits are primarily known as dental abscesses. Other abscesses appear to be rarer and therefore less well-studied, making confusion with malignant tumours more likely (Reusch, 2005).

*Picture 11 An X-ray of the abdominal mass with calcification, Veterinární klinika Zlíchov Prague, on June 7, 2023*



*Source: Own resource*

*Picture 12 An inflammatory fluid taken from the mass, Veterinární klinika Zlíchov Prague, on June 7, 2023*



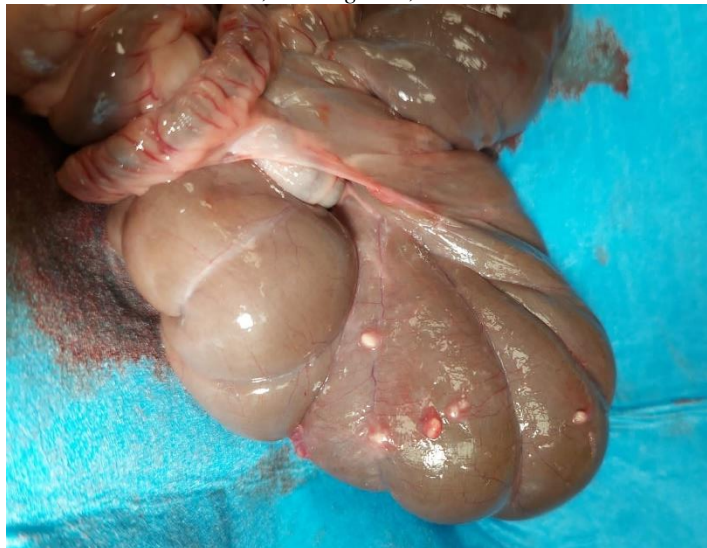*Source: Own resource*

*Picture 13 An abscess removed from the liver, Czech University of Life Sciences, On August 1, 2023*



*Source: Own resource*

*Picture 14 Small abscesses spread to other organs and resembling metastases, Czech University of Life Sciences, On August 1, 2023*



*Source: Own resource*

## 4 Conclusion

Rabbits begin to be increasingly popular pets and are among the third most common pets in the Czech Republic. With the increase in popularity, the number of cancer cases also increases. Many of the rabbit tumours mentioned above are very rare, and so unusual that they are hardly-studied and the answers to predisposition, treatment and prognosis are still unknown.

In meat and laboratory rabbits, cancer cannot be examined as much, because they do not reach a respectable age, as is the case in hobby breeding. Unless, of course, the lab rabbit is being bred for cancer research, but in most cases, it is a human cancer research and not the rabbits themselves. In wild rabbits, most cancer diseases are difficult to monitor, unless it is, for example, the cutaneous types, which are usually easily visible.

The purchase of animals from pet shops is gradually being withdrawn because their poor health status is known due to the mixed breeding. Nevertheless, even purebred breeds are prone to cancer and have a genetic predisposition to it as well. The older the rabbit, the more likely it is to have cancer. Despite this fact, thanks to humans, they live longer than in the wild. Most tumours are common in rabbits at a later age (around four years old), but lymphoma is common in young individuals. The most common tumours in rabbits are uterine adenocarcinoma, mammary adenocarcinoma, and lymphoma. Sarcomas and testicular tumours are less common, and the others are very rare exceptions. For sarcomas, males appear to have a greater predisposition, but the reason is unknown, in addition to the fact that sex hormones play a role in promoting the development of cancer. Metastases seem to be very common in rabbits and treatment is then no longer successful.

Rabbits are very sensitive to anaesthesia and postoperative complications, and in many cases the procedures are fatal. Necessary treatment of cancer for rabbits is often quite costly and difficult to achieve in all countries. As in the cases already mentioned, veterinarians do not always do a biopsy and do not consider it important to establish an accurate diagnosis. Rabbits often do not even receive timely treatment, which would likely result in a greater chance of survival. Malignant tumours are not only easily interchangeable with benign ones, but also with each other. Therefore, histological examination is very important for an accurate diagnosis.

Cancer-causing genetic mutations appear to be frequent and spontaneous in rabbits. Some tumours can be caused by heredity and a predisposition to develop cancer can be passed on through genes to their offspring. This has been most mentioned in lymphomas or thymomas, but it is more likely that the rabbit develops spontaneous mutations during its life without inheriting the gene. However, this area is probably not as well explored and more studies of rabbit cancer at the genetic level are critical for a better understanding of cancers in rabbits.

In most cases, people do not affect the development of cancer in the rabbit. Nevertheless, it is possible to try to prevent cancer through actions such as neutering, low stress behaviours, preventive examinations, and a healthy lifestyle, which all owners should be willing to provide for their rabbit.

Rabbits are complicated animals that usually show no symptoms and thus suffer longer than they are helped. As they are very small and sensitive creatures, and it is important to think about the best course of action for the rabbit (as opposed to the pet owner) after a cancer diagnosis. Providing a high quality of life without pain or suffering for the rabbit, should be of the utmost importance for the pet owner.

## 5 Bibliography

- Abbate, J. M., Palazzolo, S., Ieni, A., Rapisarda, G. S., & Lanteri, G. 2023. Cutaneous Malignant Melanoma with Testicular Metastases in a Wild Rabbit (*Oryctolagus cuniculus*). *Veterinary Sciences*, **10**(7).
- Alberts B, Johnson A, Lewis J. 2002. *Molecular Biology of the Cell*. Fourth edition. Garland Science, New York
- Albertson, D. G. 2006. Gene amplification in cancer. *Trends in Genetics*, **22**(8), 447–455.
- Alexandre N, Branco S, Soares TF, Soares J. 2010. Bilateral Testicular Seminoma in a Rabbit (*Oryctolagus cuniculus*). *J Exot Pet Med*. **19**(4):304-308.
- Alonso FH. 2022. Atypical cytomorphic description of a seminoma in a rabbit. *Vet Med Sci*. **8**(1):121.
- Anderson, M. W., Reynolds, S. H., You, M., & Maronpot, R. M. 1992. Role of proto-oncogene activation in carcinogenesis. *Environmental Health Perspectives*, **98**, 13.
- Armaghany, T., Wilson, J. D., Chu, Q., & Mills, G. 2012. Genetic Alterations in Colorectal Cancer. *Gastrointestinal Cancer Research : GCR*, **5**(1), 19.
- Arizti, P., Fang, L., Park, I., Yin, Y., Solomon, E., Ouchi, T., Aaronson, S. A., & Lee, S. W. 2000. Tumor Suppressor p53 Is Required To Modulate BRCA1 Expression. *Molecular and Cellular Biology*, **20**(20), 7450.
- Baba, A. I., & Cătoi, C. 2007. *Comparative Oncology*. The Publishing House of the Romanian Academy. Bucharest
- Bagci, O., & Kurtgöz, S. 2015. Amplification of Cellular Oncogenes in Solid Tumors. *North American Journal of Medical Sciences*, **7**(8), 341.
- Baine K, Newkirk K, Fecteau KA, Souza MJ. 2014. Elevated testosterone and progestin concentrations in a spayed female rabbit with an adrenal cortical adenoma. *Case Rep Vet Med*. doi:10.1155/2014/239410
- Banco B, Stefanello D, Giudice C, D’Acerno M, Di Giancamillo M, Grieco V. 2012. Metastasizing testicular seminoma in a pet rabbit. *Journal of Veterinary Diagnostic Investigation*. **24**(3):608-611.
- Barnes, J. L., Zubair, M., John, K., Poirier, M. C., & Martin, F. L. 2018. Carcinogens and DNA damage. *Biochemical Society Transactions*, **46**(5), 1213.

- Baum, B. 2021. Not Just Uterine Adenocarcinoma—Neoplastic and Non-Neoplastic Masses in Domestic Pet Rabbits (*Oryctolagus cuniculus*): A Review. *Veterinary Pathology*, **58**(5), 890–900.
- Bertram CA, Bertram B, Bartel A, et al. 2021. Neoplasia and Tumor-Like Lesions in Pet Rabbits (*Oryctolagus cuniculus*): A Retrospective Analysis of Cases Between 1995 and 2019. *Vet Pathol.* **58**(5):901-911.
- Borkowski R, Karas AZ. 1999. Sedation and anesthesia of pet rabbits. *Clin Tech Small Anim Pract.***14**(1):44-49.
- Boutry, J., Tissot, S., Ujvari, B., Capp, J. P., Giraudeau, M., Nedelcu, A. M., & Thomas, F. 2022. The evolution and ecology of benign tumors. *Biochimica et Biophysica Acta (BBA) - Reviews on Cancer*, **1877**(1), 188643.
- Brabb T, Di Giacomo RF. 2012. Viral Diseases. *The Laboratory Rabbit, Guinea Pig, Hamster, and Other Rodents*. 365-413. doi:10.1016/B978-0-12-380920-9.00014-6
- Brandão, J., Blair, R., Kelly, A., Fowlkes, N., Shiomitsu, K., Espinheira Gomes, F., Rich, G., & Tully, T. N. 2015. Amelanotic Melanoma in the Rabbit: A Case Report With an Overview of Immunohistochemical Characterization. *Journal of Exotic Pet Medicine*, **24**(2), 193–200.
- Brierley, J., Gospodarowicz, M., & O’Sullivan, B. 2016. The principles of cancer staging. *Ecancermedicalscience*, **10**. doi.org/10.3332/ECANCER.2016.ED61
- Brooker RJ. 2022. *Concepts of Genetics*. Fourth edition. McGraw Hill, New York
- Brown TA. 2002. Mutation, Repair and Recombination. Wiley-Liss, Oxford
- Buer CS, Muday GK, Djordjevic MA. 2007. Flavonoids Are Differentially Taken Up and Transported Long Distances in Arabidopsis. *Plant Physiology* **145**:478–490.
- Carugo, A., Minelli, R., Sapio, L., Soeung, M., Carbone, F., Robinson, F. S., Tepper, J., Chen, Z., Lovisa, S., Svelto, M., Amin, S., Srinivasan, S., del Poggetto, E., Loponte, S., Puca, F., Dey, P., Malouf, G. G., Su, X., Li, L., ... Genovese, G. 2019. p53 is a master regulator of proteostasis in SMARCB1-deficient malignant rhabdoid tumors. *Cancer Cell*, **35**(2), 204.
- Caulin, A. F., & Maley, C. C. 2011. Peto’s Paradox: Evolution’s Prescription for Cancer Prevention. *Trends in Ecology & Evolution*, **26**(4), 175.
- Chan CTT, Vella D. 2013. Pseudopregnancy. *Clinical Veterinary Advisor: Birds and Exotic Pets*. 411-412. doi:10.1016/B978-1-4160-3969-3.00182-7
- Chau, B. N., & Wang, J. Y. J. 2003. Coordinated regulation of life and death by RB. *Nature Reviews Cancer*, **3**(2), 130–138.

- Chen, J. 2016. The Cell-Cycle Arrest and Apoptotic Functions of p53 in Tumor Initiation and Progression. *Cold Spring Harbor Perspectives in Medicine*, **6**(3).
- Chin, L., & Gray, J. W. 2008. Translating insights from the cancer genome into clinical practice. *Nature*, **452**(7187), 553–563.
- Christopher C, Benz and Edison T, Liu (eds.). 1993. *ONCOGENES AND TUMOR SUPPRESSOR GENES IN HUMAN MALIGNANCIES*. Kluwer Academic Publishers, Amsterdam
- Cikanek, S. J., Carpenter, J. W., Lindemann, D. M., Hallman, R. M., Eshar, D., Kim, I. J., & Almes, K. M. 2017. Shope Fibroma in the External Ear Canal of a Domestic Rabbit. *Comparative Medicine*, **67**(1), 51.
- Cladel NM, Peng X, Christensen N, Hu J. 2019. The rabbit papillomavirus model: a valuable tool to study viral–host interactions. *Philosophical Transactions of the Royal Society B*. **374**(1773).
- Compton Z, Harris V, Rupp S, et al. 2023. Cancer Prevalence Across Vertebrates. doi:10.21203/RS.3.RS-3117313/V1
- Cox, A. D., & Der, C. J. 2010. Ras history: The saga continues. *Small GTPases*, **1**(1), 2.
- Cruz-Gálvez, C. C., Ordaz-Favila, J. C., Villar-Calvo, V. M., Cancino-Marentes, M. E., & Bosch-Canto, V. 2022. Retinoblastoma: Review and new insights. *Frontiers in Oncology*, **12**. doi: 10.3389/fonc.2022.963780
- Das, A., Saha, A., Pattari, S., & Narayan, P. 2022. Myxofibrosarcoma or myxoma: malignant transformation or misdiagnosis. *Indian Journal of Thoracic and Cardiovascular Surgery*, **38**(3), 290.
- Degner, S., Schoon, H. A., Laik-Schandelmaier, C., Aupperle-Lellbach, H., & Schöniger, S. 2018. Estrogen Receptor– $\alpha$  and Progesterone Receptor Expression in Mammary Proliferative Lesions of Female Pet Rabbits. *Veterinary Pathology*, **55**(6), 838–848.
- Disis, M. L. 2010. Immune Regulation of Cancer. *Journal of Clinical Oncology*, **28**(29), 4531.
- Ewald, P. W., & Swain Ewald, H. A. 2019. The scope of viral causation of human cancers: interpreting virus density from an evolutionary perspective. *Philosophical Transactions of the Royal Society B: Biological Sciences*, **374**(1773).
- Fernández-Medarde, A., & Santos, E. 2011. Ras in Cancer and Developmental Diseases. *Genes & Cancer*, **2**(3), 344.

Fernández-Medarde, A., de Las Rivas, J., & Santos, E. 2021. 40 Years of RAS—A Historic Overview. *Genes*, **12**(5).

Fox, R. R., Meier, H., & Crary, D. D. 1971. Genetic predisposition to tumors in the rabbit. *Die Naturwissenschaften*, **58**(9), 457.

Frangne N, Eggmann T, Koblichke C, Weissenbock G, Martinoia E, Klein M. 2002. Flavone Glucoside Uptake into Barley Mesophyll and Arabidopsis Cell Culture Vacuoles. Energization Occurs by H<sup>+</sup>-Antiport and ATP-Binding Cassette-Type Mechanisms. *Plant Physiology* **128**:726–733.

Elmore, S. 2007. Apoptosis: A Review of Programmed Cell Death. *Toxicologic Pathology*, **35**(4), 495.

Gazendam, A., Popovic, S., Parasu, N., & Ghert, M. 2023. Chondrosarcoma: A Clinical Review. *Journal of Clinical Medicine*, **12**(7), 2506.

Gómez L, Gázquez A, Roncero V, Sánchez C, Durán ME. 2002. Lymphoma in a rabbit: histopathological and immunohistochemical findings. *Journal of Small Animal Practice*. **43**(5):224-226.

Gonzalez H, Hagerling C, Werb Z. 2018. Roles of the immune system in cancer: from tumor initiation to metastatic progression. *Genes Dev*. **32**(19-20):1267.

Guillerman, R. P., Voss, S. D., & Parker, B. R. 2011. Leukemia and Lymphoma. *Radiologic Clinics*, **49**(4), 767–797.

Guzman, R. E., Ehrhart, E. J., Wasson, K., & Andrews, J. J. 2000. Primary hepatic hemangiosarcoma with pulmonary metastasis in a New Zealand White rabbit. *Journal of Veterinary Diagnostic Investigation*, **12**(3), 284–286.

Hall, J. F. 2015. Management of Malignant Adenomas. *Clinics in Colon and Rectal Surgery*, **28**(4), 215.

Heatley, J. J., & Smith, A. N. 2004. Spontaneous neoplasms of lagomorphs. *Veterinary Clinics of North America: Exotic Animal Practice*, **7**(3), 561–577.

Higgins, S., Sanchez-Migallon Guzman, D., Sadar, M. J., Burton, A., LaDouceur, E., Bucy, D., Rodriguez, C. O., Harvey, C., & Hunt, G. 2015. Coxofemoral Amputation in a Domestic Rabbit (*Oryctolagus Cuniculus*) With Tibiofibular Osteoblastic Osteosarcoma. *Journal of Exotic Pet Medicine*, **24**(4), 455–463.

Hinze HC. 1971. Induction of lymphoid hyperplasia and lymphoma-like disease in rabbits by herpesvirus sylvilagus. *Int J Cancer*. **8**(3):514-522.



- Hobbs, G. A., Der, C. J., & Rossman, K. L. 2016. RAS isoforms and mutations in cancer at a glance. *Journal of Cell Science*, **129**(7), 1287–1292.
- Hodgson, S. 2008. Review: Mechanisms of inherited cancer susceptibility. *Journal of Zhejiang University. Science. B*, **9**(1), 1.
- Hong, J., Lee, J. M., Lee, J. Y., Lee, H. J., Lee, D. K., Song, J. H., & Song, K. H. 2023. Surgery and Metronomic Chemotherapy in a Pet Rabbit (*Oryctolagus cuniculus*) with Mammary Gland Adenocarcinoma. *Journal of Veterinary Clinics*, **40**(6), 445–451.
- Hori, S. S., & Gambhir, S. S. 2011. Mathematical model identifies blood biomarker-based early cancer detection strategies and limitations. *Science Translational Medicine*, **3**(109).
- Huston SM, Ming-Show Lee P, Quesenberry KE, Pilny AA. 2012. Cardiovascular Disease, Lymphoproliferative Disorders, and Thymomas. *Ferrets, Rabbits, and Rodents*. 257. doi:10.1016/B978-1-4160-6621-7.00020-8
- Imran, A., Qamar, H. Y., Ali, Q., Naeem, H., Riaz, M., Amin, S., Kanwal, N., Ali, F., Sabar, M. F., & Nasir, I. A. 2017. Role of Molecular Biology in Cancer Treatment: A Review Article. *Iranian Journal of Public Health*, **46**(11), 1475.
- Irizarry-Rovira AR, Lennox AM, Ramos-Vara JA. 2008. Granular cell tumor in the testis of a rabbit: Cytologic, histologic, immunohistochemical, and electron microscopic characterization. *Vet Pathol*. **45**(1):73-77.
- Ishikawa, M., Kondo, H., Onuma, M., Shibuya, H., & Sato, T. 2012. Osteoblastic Osteosarcoma in a Rabbit. *Comparative Medicine*, **62**(2), 124.
- Ishikawa M, Maeda H, Kondo H, Shibuya H, Onuma M, Sato T. 2007. A Case of Lymphoma Developing in the Rabbit Cecum. *Journal of Veterinary Medical Science*. **69**(11):1183-1185.
- Jeandet P, Hébrard C, Deville M-A, Cordelier S, Dorey S, Aziz A, Crouzet J. 2014. Deciphering the Role of Phytoalexins in Plant-Microorganism Interactions and Human Health. *Molecules* **19**:18033–18056.
- Jensen, R. A. 2001. Orthologs and paralogs - we need to get it right. *Genome Biology*, **2**(8),
- Karnoub, A. E., & Weinberg, R. A. 2008. Ras oncogenes: split personalities. *Nature Reviews. Molecular Cell Biology*, **9**(7), 517.
- Kato, S., Han, S. Y., Liu, W., Otsuka, K., Shibata, H., Kanamaru, R., & Ishioka, C. 2003. Understanding the function–structure and function–mutation relationships of p53 tumor suppressor protein by high-resolution missense mutation analysis. *Proceedings of the National Academy of Sciences of the United States of America*, **100**(14), 8424.

- Kawakami Y. 2016. Introduction: Cancer Immunology Special Issue—Immunopathology. *Int Immunol.* **28**(8):371-371.
- Keller KA, Sanchez-Migallon Guzman D, Reilly C, et al. 2019. POST-TRAUMATIC OCULAR LYMPHOMA IN THREE RABBITS (ORYCTOLAGUS CUNICULUS). *J Exot Pet Med.* **28**:154-161.
- Kerr, P. J. 2020. Rabbit Myxoma Virus and the Fibroma Viruses (Poxviridae). *Encyclopedia of Virology: Volume 1-5, Fourth Edition, 1–5*, 730–737.
- Kandefler-Gola, M., Żebrowski, K., Ciaputa, R., Borawski, W., Brambilla, E., & Grieco, V. 2022. Tracheal Hemangioma Causing Lung Emphysema and Pneumopericardium in a Rabbit—A Case Report. *Animals : An Open Access Journal from MDPI*, **12**(15).
- Kershaw O. 2016. Tumors of Mice, Rats, Rabbits, and Guinea Pigs. *Veterinary Oncology.* 293-309. doi:10.1007/978-3-319-41124-8\_19
- King, A. M., Posthumus, J., Hammond, G., & Sullivan, M. 2012. Comparison of ultrasonography, radiography and a single computed tomography slice for the identification of fluid within the tympanic bulla of rabbit cadavers. *The Veterinary Journal*, **193**(2), 493–497.
- Knudson AG. 2003. Cancer genetics through a personal retrospectroscope. *Genes Chromosomes Cancer.* **38**(4):288-291.
- Kondo, H., Ishikawa, M., Maeda, H., Onuma, M., Masuda, M., Shibuya, H., Koie, H., & Sato, T. 2007. Spontaneous osteosarcoma in a rabbit (*Oryctolagus cuniculus*). *Veterinary Pathology*, **44**(5), 691–694.
- Korstanje, R., O'Brien, P. C. M., Yang, F., Rens, W., Bosma, A. A., van Lith, H. A., van Zutphen, L. F. M., & Ferguson-Smith, M. A. 1999. Complete homology maps of the rabbit (*Oryctolagus cuniculus*) and human by reciprocal chromosome painting. *Cytogenetics and Cell Genetics*, **86**(3–4), 317–322.
- Kozlov, A. P. 2022. Mammalian tumor-like organs. 1. The role of tumor-like normal organs and atypical tumor organs in the evolution of development (carcino-evo-devo). *Infectious Agents and Cancer*, **17**(1), 1–15.
- Kreider JW, Bartlett GL. 1981. The Shope Papilloma-Carcinoma Complex of Rabbits: A Model System of Neoplastic Progression and Spontaneous Regression. *Adv Cancer Res.* **35**(C):81-110.
- Largeot, A., Pagano, G., Gonder, S., Moussay, E., & Paggetti, J. 2019. The B-Side of Cancer Immunity: The Underrated Tune. *Cells*, **8**(5).

- Lawrence J, Cameron D, Argyle D. 2015. Species differences in tumour responses to cancer chemotherapy. *Philosophical Transactions of the Royal Society B: Biological Sciences*. **370**(1673).
- Lee, H. W., Machin, H., & Adami, C. 2018. Peri-anaesthetic mortality and nonfatal gastrointestinal complications in pet rabbits: a retrospective study on 210 cases. *Veterinary Anaesthesia and Analgesia*, **45**(4), 520–528.
- Lee YR, Chen M, Pandolfi PP. 2018. The functions and regulation of the PTEN tumour suppressor: new modes and prospects. *Nat Rev Mol Cell Biol*. **19**(9):547-562.
- Lennox AM, Chitty J. 2006. Adrenal Neoplasia and Hyperplasia as a Cause of Hypertestosteronism in Two Rabbits. *J Exot Pet Med*. **15**(1):56-58.
- Li, B., Huang, Q., & Wei, G. H. 2019. The Role of HOX Transcription Factors in Cancer Predisposition and Progression. *Cancers*, **11**(4).
- Liu, Y., & Sheikh, M. S. 2014. Melanoma: Molecular Pathogenesis and Therapeutic Management. *Molecular and Cellular Pharmacology*, **6**(3), 228.
- McCormick, F. 1991. GTP-binding proteins as oncogenes in human tumors. *Environmental Health Perspectives; (United States)*, **93**, 17–18.
- McLaughlin, A., Tripp, C., Bertram, C. A., Kiupel, M., Thaiwong, T., & Reavill, D. 2021. Cutaneous squamous cell carcinomas in domestic rabbits (*Oryctolagus cuniculus*): 39 cases (1998-2019). *Journal of Exotic Pet Medicine*, **39**, 38–50.
- Millward, L. (2020). Rabbit. *Veterinary Cytology*, 766–781. <https://doi.org/10.1002/9781119380559.CH57>
- Mikiewicz, M., Paździor-Czapula, K., Gesek, M., Dziubińska-Bartylak, P., & Otrócka-Domagala, I. 2020. Intraocular Chondrosarcoma in a Rabbit. *Journal of Comparative Pathology*, **179**, 41–44.
- Moore DM, Zimmerman K, Smith SA. 2015. Hematological Assessment in Pet Rabbits: Blood Sample Collection and Blood Cell Identification. *Veterinary Clinics of North America: Exotic Animal Practice*. **18**(1):9-19.
- Moosavi, A., & Ardekani, A. M. 2016. Role of Epigenetics in Biology and Human Diseases. *Iranian Biomedical Journal*, **20**(5), 246.
- Mordstein, C., Cano, L., Morales, A. C., Young, B., Ho, A. T., Rice, A. M., Liss, M., Hurst, L. D., & Kudla, G. 2021. Transcription, mRNA Export, and Immune Evasion Shape the Codon Usage of Viruses. *Genome Biology and Evolution*, **13**(9).

- Mullangi, S., & Lekkala, M. R. 2023. Adenocarcinoma. *Uro pathology, Second Edition*, 263–264. [doi.org/10.1016/B978-0-323-65395-4.00125-1](https://doi.org/10.1016/B978-0-323-65395-4.00125-1)
- Murakami, M., Yonemaru, K., Hirata, A., & Sakai, H. 2024. Uterine haemangiosarcoma in a Netherland Dwarf rabbit (*Oryctolagus cuniculus* Netherland dwarf). *Veterinary Medicine and Science*, **10**(1), e1311.
- Nambiar M, Kari V, Raghavan SC. 2008. Chromosomal translocations in cancer. *Biochimica et Biophysica Acta (BBA) - Reviews on Cancer*. **1786**(2):139-152.
- Orr, B., Godek, K. M., & Compton, D. 2015. Aneuploidy. *Current Biology : CB*, **25**(13), R538.
- Ozaki, T., & Nakagawara, A. 2011. Role of p53 in Cell Death and Human Cancers. *Cancers*, **3**(1), 994.
- Palmer A, Wu CC, Miwa Y, Turek M, Sladky KK. 2021. Outcomes and survival times of client-owned rabbits diagnosed with thymoma and treated with either prednisolone or radiotherapy, or left untreated. *J Exot Pet Med*. **38**:35-43.
- Palucka AK, Coussens LM. 2016. The Basis of Oncoimmunology. *Cell*. **164**(6):1233-1247.
- Pardoll D. 2015. Cancer and the Immune System: Basic Concepts and Targets for Intervention. *Semin Oncol*. **42**(4):523.
- Parham P. 2014. *The Immune System*. Fourth edition. Taylor & Francis, New York
- Park, C. H., Nakajima, C., Kimitsuki, K., Shiwa, N., Tsuchida, Y., & Boonsriroj, H. (2016). Subcutaneous rhabdomyosarcoma in an old rabbit. *The Journal of Veterinary Medical Science*, **78**(9), 1525.
- Park, H. S., Kim, S. H., Rho, J. H., Kwun, H. J., & Son, H. Y. 2020. Uterine leiomyosarcoma in a lion-head rabbit. *Journal of Veterinary Clinics*, **37**(2), 109–113.
- Pawlak-Sprada S, Stobiecki M, Deckert J. 2011. Activation of phenylpropanoid pathway in legume plants exposed to heavy metals. Part ii. Profiling of isoflavonoids and their glycoconjugates induced in roots of lupine (*Lupinus luteus*) seedlings treated with cadmium and lead. *Acta Biochimica Polonica* **58**:217–223.
- Petterino, C., Modesto, P., Strata, D., Vascellari, M., Mutinelli, F., Ferrari, A., & Ratto, A. 2009. A case of interscapular fibrosarcoma in a dwarf rabbit (*Oryctolagus cuniculus*). *Journal of Veterinary Diagnostic Investigation*, **21**(6), 900–905.
- Pilny AA, Reavill D. 2008. Chylothorax and Thymic Lymphoma in a Pet Rabbit (*Oryctolagus cuniculus*). *J Exot Pet Med*. **17**(4):295-299.

- Piña-Sánchez, P., Chávez-González, A., Ruiz-Tachiquín, M., Vadillo, E., Monroy-García, A., Montesinos, J. J., Grajales, R., Gutiérrez de la Barrera, M., & Mayani, H. 2021. Cancer Biology, Epidemiology, and Treatment in the 21st Century: Current Status and Future Challenges From a Biomedical Perspective. *Cancer Control : Journal of the Moffitt Cancer Center*, **28**, 1–21.
- Pires PP, Kanegae MY, Rays J, et al. 2016. Diffuse large B-cell lymphoma presenting in the leukemic phase. *Autops Case Rep.* **6**(1):41.
- Pogribny, I. P., & Rusyn, I. 2013. Environmental toxicants, epigenetics, and cancer. *Advances in Experimental Medicine and Biology*, **754**, 215.
- Prior, I. A., Lewis, P. D., & Mattos, C. 2012. A comprehensive survey of Ras mutations in cancer. *Cancer Research*, **72**(10), 2457.
- Reusch B. Rabbit Gastroenterology. 2005. *Vet Clin North Am Exot Anim Pract.* **8**(2):351.
- Rioja-Lang, F., Bacon, H., Connor, M., & Dwyer, C. M. 2019. Original research: Rabbit welfare: determining priority welfare issues for pet rabbits using a modified Delphi method. *Veterinary Record Open*, **6**(1), 363.
- Ritter JM, von Bomhard W, Wise AG, Maes RK, Kiupel M. 2012. Cutaneous Lymphomas in European Pet Rabbits (*Oryctolagus cuniculus*). *Vet Pathol.* **49**(5):846-851.
- Robertson JA, Guzman DSM, Willcox JL, Keel K, Vernau W. 2022. Clinical and pathological findings of rabbits with lymphoma: 16 cases (1996–2019). *J Am Vet Med Assoc.* **260**(9):1-10.
- Sansregret, L., & Swanton, C. 2017. The Role of Aneuploidy in Cancer Evolution. *Cold Spring Harbor Perspectives in Medicine*, **7**(1).
- Schöniger S, Degner S, Jasani B, Schoon HA. 2019. A Review on Mammary Tumors in Rabbits: Translation of Pathology into Medical Care. *Animals 2019, Vol 9, Page 762.* **9**(10):762.
- Schöniger S, Horn LC, Schoon HA. 2014. Tumors and Tumor-like Lesions in the Mammary Gland of 24 Pet Rabbits: A Histomorphological and Immunohistochemical Characterization. *Vet Pathol.* **51**(3):569-580.
- Schwab M. 1999. Oncogene amplification in solid tumors. *CANCER BIOLOGY.* **9**: 319-325.
- Seyfried, T. N., & Huysentruyt, L. C. 2013. On the Origin of Cancer Metastasis. *Critical Reviews in Oncogenesis*, **18**(1–2), 43.
- Sharma, S., Kelly, T. K., & Jones, P. A. 2010. Epigenetics in cancer. *Carcinogenesis*, **31**(1), 27.

- Shope RE, Hurst EW. 1933. INFECTIOUS PAPILLOMATOSIS OF RABBITS WITH A NOTE ON THE HISTOPATHOLOGY. *Journal of Experimental Medicine*. **58**(5):607-624.
- Shou, H., Wu, J., Tang, N., & Wang, B. 2022. Calcification-Based Cancer Diagnosis and Therapy. *ChemMedChem*, **17**(4), e202100339.
- Sommerville LM. 1998. Treatment of a uterine adenocarcinoma in a domestic rabbit by ovariectomy. *Vet Rec*. **142**(20):550-551.
- Spranger, S. 2016. Mechanisms of tumor escape in the context of the T-cell-inflamed and the non-T-cell-inflamed tumor microenvironment. *International Immunology*, **28**(8), 383–391.
- Spurrell EL, Lockley M. 2014. Adaptive immunity in cancer immunology and therapeutics. *Ecancermedicalscience*. **8**(1).
- Srivastava, S., & Grizzle, W. E. 2010. BIOMARKERS AND THE GENETICS OF EARLY NEOPLASTIC LESIONS. *Cancer Biomarkers : Section A of Disease Markers*, **9**(1–6), 41.
- Stans, J. 2023. AN OVERVIEW OF RECENT OSTEOSARCOMA CASES IN RABBITS (*Oryctolagus cuniculus*). *Egyptian Journal of Rabbit Science*, **33**(1), 35–42.
- Summa NM, Eshar D, Snyman HN, Lillie BN. 2014. Metastatic anaplastic adenocarcinoma suspected to be of mammary origin in an intact male rabbit (*Oryctolagus cuniculus*). *The Canadian Veterinary Journal*. **55**(5):475.
- Tamaru, H. 2010. Confining euchromatin/heterochromatin territory: jumonji crosses the line. *Genes & Development*, **24**(14), 1465.
- Tartarone, A., Lerose, R., Lettini, A. R., & Tartarone, M. 2023. Current Treatment Approaches for Thymic Epithelial Tumors. *Life*, **13**(5).
- Tinkey PT, Uthamanthil RK, Weisbroth SH. 2012. Rabbit Neoplasia. *The Laboratory Rabbit, Guinea Pig, Hamster, and Other Rodents*. 447-501. doi:10.1016/B978-0-12-380920-9.00016-X
- Torpy, J. M., Lynn, C., & Glass, R. M. 2010. Cancer: The Basics. *JAMA*, **304**(14), 1628–1628.
- Ueda, K., Ueda, A., & Ozaki, K. 2018. Cutaneous malignant melanoma in two rabbits (*Oryctolagus cuniculus*). *The Journal of Veterinary Medical Science*, **80**(6), 973.
- Vallentin B, Barlogis V, Piperoglou C, et al. 2015. Innate Lymphoid Cells in Cancer. *Cancer Immunol Res*. **3**(10):1109-1114.

- van der Groep, P., Bouter, A., van der Zanden, R., Siccama, I., Menko, F. H., Gille, J. J. P., van Kalken, C., van der Wall, E., Verheijen, R. H. M., & van Diest, P. J. 2006. Distinction between hereditary and sporadic breast cancer on the basis of clinicopathological data. *Journal of Clinical Pathology*, **59**(6),
- van Zeeland Y. 2017. Rabbit Oncology: Diseases, Diagnostics, and Therapeutics. *Veterinary Clinics of North America: Exotic Animal Practice*. **20**(1):135-182.
- Varmus, H. 2009. *The Art and Politics of Science*. W.W. Norton & Company, New York
- Vennen KM, Mitchell MA. 2009. RABBITS. *Manual of Exotic Pet Practice*. 375-405. doi:10.1016/B978-141600119-5.50017-2
- Vermeulen, K., van Bockstaele, D. R., & Berneman, Z. N. 2003. The cell cycle: a review of regulation, deregulation and therapeutic targets in cancer. *Cell Proliferation*, **36**(3), 131.
- Villegas M, Sommarin M, Brodelius PE. 2000. Effects of sodium orthovanadate on benzophenanthridine alkaloid formation and distribution in cell suspension cultures of *Eschscholtzia californica*. *Plant Physiology and Biochemistry* **38**:233–241.
- Vinci A, Bacci B, Benazzi C, Caldin M, Sarli G. 2010. Progesterone receptor expression and proliferative activity in uterine tumours of pet rabbits. *J Comp Pathol*. **142**(4):323-327.
- Vodanovich, D., & Choong, P. M. 2018. Soft-tissue Sarcomas. *Indian Journal of Orthopaedics*, **52**(1), 35.
- Volopich S, Gruber A, Hassan J, Hittmair KM, Schwendenwein I, Nell B. 2005. Malignant B-cell lymphoma of the Harder's gland in a rabbit. *Vet Ophthalmol*. **8**(4):259-263.
- von Bomhard, W., Goldschmidt, M. H., Shofer, F. S., Perl, L., Rosenthal, K. L., & Mauldin, E. A. 2007. Cutaneous neoplasms in pet rabbits: A retrospective study. *Veterinary Pathology*, **44**(5), 579–588.
- Wagner, F., Beinecke, A., Fehr, M., Brunkhorst, N., Mischke, R., & Gruber, A. D. 2005. Recurrent bilateral exophthalmos associated with metastatic thymic carcinoma in a pet rabbit. *Journal of Small Animal Practice*, **46**(8), 393–397.
- Wajed, S. A., Laird, P. W., & DeMeester, T. R. 2001. DNA Methylation: An Alternative Pathway to Cancer. *Annals of Surgery*, **234**(1), 10.
- Walter B, Poth T, Böhmer E, Braun J, Matis U. 2010. Uterine disorders in 59 rabbits. *Vet Rec*. **166**(8):230-233.

Wang, G., Chen, L., Yu, B., Zellmer, L., Xu, N., & Liao, D. J. 2016. Learning about the Importance of Mutation Prevention from Curable Cancers and Benign Tumors. *Journal of Cancer*, **7**(4), 436.

Wang LH, Wu CF, Rajasekaran N, Shin YK. 2019. Loss of Tumor Suppressor Gene Function in Human Cancer: An Overview. *Cellular Physiology and Biochemistry*. **51**(6):2647-2693.

Weinhold, B. 2006. Epigenetics: The Science of Change. *Environmental Health Perspectives*, **114**(3), A160.

Wijesundera, K. K., Izawa, T., Fujita, D., Denda, Y., Seto, E., Sasai, H., Kuwamura, M., & Yamate, J. 2013. Spontaneous Extraskelatal Osteosarcoma in a Rabbit (*Oryctolagus cuniculus*): Histopathological and Immunohistochemical Findings. *Journal of Toxicologic Pathology*, **26**(3), 309.

Wright, T., Wilson, P., Kundahar, R., Schrire, T., Coelho, J., & Chapman, T. 2023. Sarcoma. *Textbook of Plastic and Reconstructive Surgery: Basic Principles and New Perspectives*, 371–380. doi: 10.1007/978-3-030-82335-1\_24

Ye Y, Ding Y, Jiang Q, Wang F, Sun J, Zhu C. 2017. The role of receptor-like protein kinases (RLKs) in abiotic stress response in plants. *Plant Cell Reports* **36**:235–242.

Zhao, X., Singhal, A., Park, S., Kong, J., Bachelder, R., & Ideker, T. 2024. Cancer Mutations Converge on a Collection of Protein Assemblies to Predict Resistance to Replication Stress. *Cancer Discovery*, **14**(3), 508–523.

Zingde, S. M. 1993. Cancer genes. *Western Journal of Medicine*, **158**(3), 273.

## Websites

Beer, R., 2019. Science Surgery: ‘Why doesn’t the immune system attack cancer cells?’. Available at <https://news.cancerresearchuk.org/2019/02/28/science-surgery-why-doesnt-the-immune-system-attack-cancer-cells/> (accessed September 21, 2023)

Cancer Classification | SEER Training. Available at <https://training.seer.cancer.gov/disease/categories/classification.html> (accessed September 17, 2023)

Castellino AM. 2015. Why Elephants Don’t Get Cancer, at Least Not Often. Available at [www.medscape.com/viewarticle/852363](http://www.medscape.com/viewarticle/852363) (accessed September 18, 2023)



Garcez T.N.A., Teixeira F.S., Beheregaray W.K., Oliveira R.T., Cardoso C.S., Fernandes A.O., Gianotti G.C., Gomes C., Contesini E.A. 2009. Myxoid Chondrosarcoma in a Rabbit. Available at <https://www.vin.com/doc/?id=4252929> (accessed March 2024)

Genetic Mutations | Types of Mutations | American Cancer Society. Available at <https://www.cancer.org/cancer/understanding-cancer/genes-and-cancer/gene-changes.html> (accessed September 18, 2023)

*Health and welfare information about your rabbit from Vetlexicon Lapis.* Available at <http://crossriggsvets.co.uk> (accessed February 12, 2024)

Joyce, C., Rayi, A., & Kasi, A. 2023. Tumor-Suppressor Genes. *StatPearls*. Available at <https://www.ncbi.nlm.nih.gov/books/NBK532243/> (accessed March 10, 2024)

Small Animal Veterinary Association World Congress Proceedings Available at <https://www.vin.com/apputil/content/defaultadv1.aspx?pId=11290&catId=33317&id=4252929> (accessed March, 2024)

Stages of cancer | Cancer Research UK. Available at <https://www.cancerresearchuk.org/about-cancer/what-is-cancer/stages-of-cancer> (accessed September 19, 2023)

(US), N. I. of H., & Study, B. S. C. 2007. *Understanding Cancer*. Available at <https://www.ncbi.nlm.nih.gov/books/NBK20362/> (accessed September 22, 2023)

Yiallourous, M., & Kube, S. (2010). Weichteilsarkome und seltene Weichteiltumoren (Kurzinformation). *Weichteilsarkome Und Seltene Weichteiltumoren (Kurzinformation)*. Available at <https://doi.org/10.1591/POH.PATINFO.WEICHTEILTUMOR.KURZ.20101215> (accessed March 18, 2024)

Zafar, R., & Wheeler, Y. 2023. Liposarcoma. *StatPearls*. Available at: <https://www.ncbi.nlm.nih.gov/books/NBK538265/> (accessed March 20, 2024)



